

# Maxillary first premolar with three roots: Case report

Fausto Rodrigo **VICTORINO**<sup>1</sup>

Christine **MEN-MARTINS**<sup>2</sup>

## ABSTRACT

**Introduction:** The maxillary first premolar may rarely present with three roots, two buccal and one palatal, demanding more attention during endodontic intervention. **Objective:** This paper reports the case of a maxillary first premolar with three roots and three root canals, highlighting the difficulties and special care during endodontic treatment. **Methods:** After initial radiography and coronal opening, the presence of three roots and three root canals was detected. The exploration of the canals was performed with #10 K-file and the root canal length was measured by means of radiographic

technique, which made it possible to confirm the anatomical variation and to assure that the buccal canals were independent. The instrumentation was mixed, with K-type hand files, until #35 file, automatized with Pro-Taper® system (Dentsply). The filling of the canals was performed with the lateral compaction technique with sealer Sealer 26®. **Conclusion:** Professionals should always carefully consider the diagnostic radiograph and perform all steps of root canal treatment properly, so that possible changes can be detected, not compromising the success of treatment.

**Keywords:** Anatomy. Bicuspid. Dental pulp cavity.

**How to cite this article:** Victorino FR, Men-Martins C. Maxillary first premolar with three roots: Case report. *Dental Press Endod.* 2013 Jan-Apr;3(1):73-7.

» The authors report no commercial, proprietary or financial interest in the products or companies described in this article.

Received: April 17, 2013. Accepted: April 19, 2013.

<sup>1</sup>Professor of Endodontics, CESUMAR.

<sup>2</sup>MSc in Dentistry, UNESP. PhD student in Dental Sciences, UNESP.

Contact address: Fausto Rodrigo Victorino  
Rua Formosa, 489 – Centro – Marialva/PR – CEP: 86.990-000 – Brazil

## Introduction

The thorough knowledge of dental anatomy is extremely important to the success of endodontic treatment, which is composed of several interdependent steps.<sup>1,8,9,12,14,18,20</sup> Roots and root canals can vary in number, size, shape, divisions, fusions, directions and stages of development.<sup>9</sup> The periapical radiographs help in the study of internal anatomy and its variants,<sup>8,9</sup> and, for better viewing, we recommend the use of two diagnostic radiographs, a orthoradial and another mesially or distally displaced.<sup>10</sup>

Often, the first premolar presents itself with two conical roots, one buccal and one palatal, and two respective canals.<sup>9,12</sup> These roots may present themselves independent, not entirely separate or as a single root.<sup>9</sup>

However, this dental element may have many variations, especially in the amount of roots.<sup>9,12,20</sup> The buccal root, sometimes, is divided into two: Mesio-vestibular root and distobuccal root.<sup>9,12</sup> In this case the tooth is called “minimolar”.<sup>12</sup> This format was described with a frequency of 2.5% by Pécora et al<sup>15</sup> and 3.3% by Chaparro et al.<sup>4</sup> The presence of the third canal in first premolars regardless of the

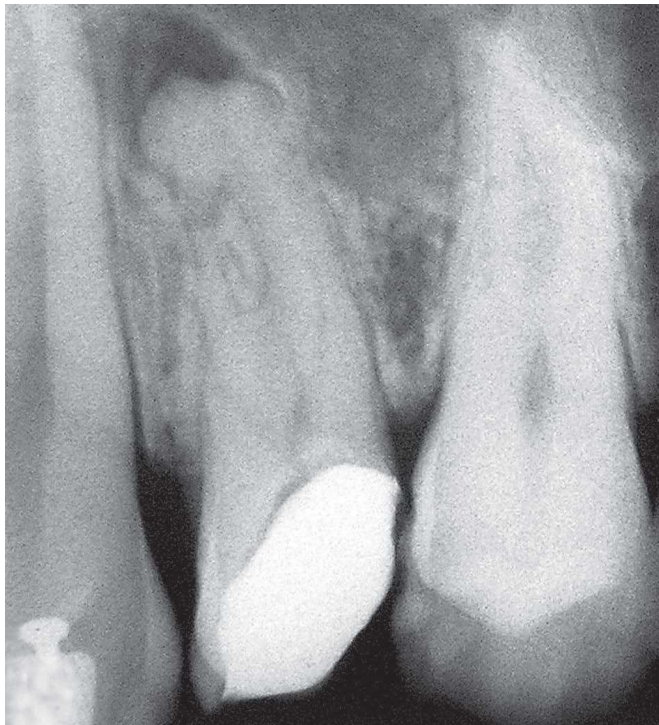number of roots was reported in 1979, by Vertucci and Gegauff,<sup>19</sup> which examined 400 extracted teeth and found a prevalence of 5%. Recently, in 2008, Rózylo et al<sup>16</sup> described the presence of the third canal in 9% of the cases.

Thus, the objective of this paper is to present, by means of a clinical case, a rare anatomical variation of the first premolar with three roots and three root canals, and its implications in endodontic treatment.

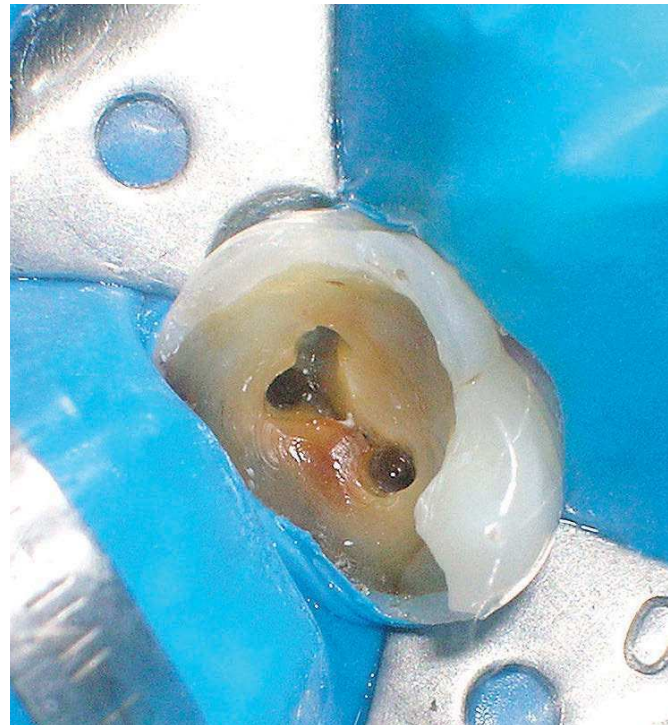
## Case report

Male patient, 32-years-old, attended the service of endodontics, School of Dentistry of Bauru/SP, conveyed from the public health system to perform endodontic treatment of tooth #14.

Radiographically, it was observed unusual root anatomy, suggestive of two buccal roots and one palatal root (Fig 1). After performing anesthesia, access cavities and rubber dam, it was confirmed the presence of two vestibular sockets, making the final shape triangular, with a base facing the buccal aspect (Fig 2). The exploration of the canals was performed with #10 K-file and the root canal length was measured



**Figure 1.** Initial radiographic examination of tooth #14, suggesting triradicular premolar.



**Figure 2.** Triangular shape and presence of three roots.

by means of radiographic technique, enabling to confirm the variation in morphology and to assure that both canals were independent (Fig 3). The instrumentation was mixed, and the apical preparation was performed with K-type hand files, until #35 file; cervical and middle thirds were prepared with ProTaper® automated system (Dentsply).

Due to the presence of apical lesions, we used calcium hydroxide (Ca[OH]<sub>2</sub>) as an intracanal medication for a month. After this period, it was performed the filling of the canal with the lateral compaction technique with Sealer 26® (Fig 4).

In the X-ray control, achieved after two years, it was observed a normal aspect of periapical region structures (Fig 5).

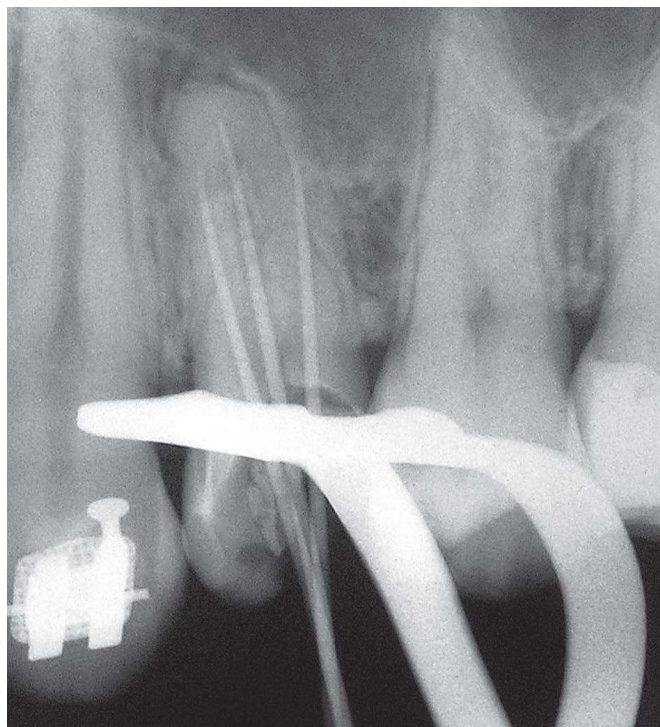
## Discussion

The thorough knowledge of dental anatomy is of utmost importance for the completion of endodontic treatment,<sup>1,8,9,12,14,18,20</sup> because is through this science that the dentist can estimate a three-dimensional situation of the canal system, from a two-dimensional image provided by radiographs.<sup>8</sup>

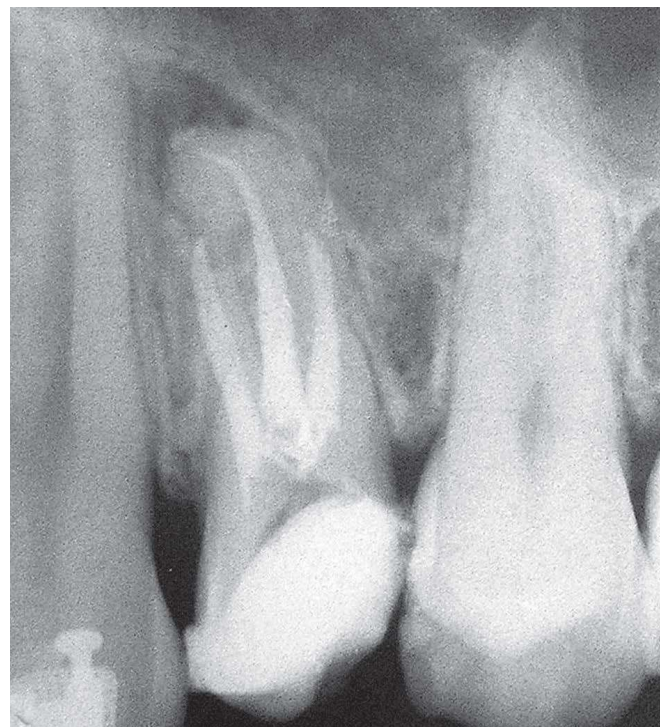
Over the years, literature has reported the most varied anatomical changes of several teeth, including premolars.<sup>1</sup> These variations may be related to the number of root canal, its size, shape, divisions, fusions, directions and stages of development.<sup>9</sup>

Premolars are a group of teeth exclusive of the permanent dentition, and their predecessor are the first deciduous molars. They also have the basic function of crushing and grinding food, in addition to helping the speech and aesthetics. The first premolar has an average length of 21.5 mm, ranging from 17 to 25.5 mm.<sup>7</sup> In most cases, they feature two conical roots — one buccal and one palatal — with one canal each one, and the vestibular root often presents a curvature towards the palatine aspect.<sup>7,9,12</sup> These roots may be well developed, not entirely separate or as a single and large root, with two canals in its interior.<sup>7,9</sup> The outline of the pulp chamber has an elliptical morphology, due to the mesiodistal flattening.<sup>9</sup>

However, the amount of roots and canals can vary in this dental group,<sup>9,12,14,18,20</sup> since the buccal root may divide into two,<sup>7</sup> evidencing mesiovestibular and distobuccal roots. In this case, the premolar may be



**Figure 3.** Root canal length, showing the presence of three root canals.



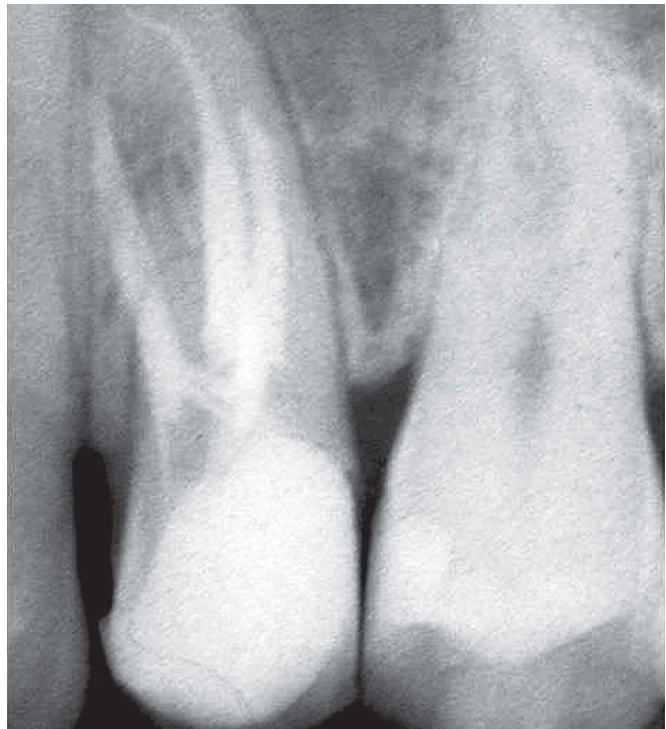**Figure 4.** Final aspect of tooth #14 endodontic treatment.

referred to as a “minimolar”.<sup>12</sup> According to Bellizzi and Hartwell,<sup>2</sup> when this change in morphology occurs, the roots can be classified into three groups. In group 1 the three roots are merged or there is only two buccal roots, and the palatal root is semifused or free. In group 2 buccal roots present separate, from middle or apical third. In group 3 the three roots are separate from the cervical third. In this case reported, there was no certainty about the classification, since the radiographic images allow a subjective understanding on roots separation (Figs 1, 3 and 4).

Endodontic treatment of maxillary premolars with this morphology should be adjusted to such a situation, by locating all existing root canals and making the outline change from elliptical<sup>7,8,9</sup> to triangular, with the base toward the buccal aspect and the apex to the lingual aspect. In the case reported, it could be seen that by making the coronal opening, due care has been taken regarding the location of the canals, which was more difficult due to the great loss of coronal structure, in particular at the distal aspect of the tooth (Fig 2).

Regarding the instrumentation employed, the use of hand files is established for confection of apical stop,<sup>7,8,9</sup> and ProTaper® system consists of rotary instruments that have proven effective, improved and simplified, allowing the professional to perform more effectively and quickly the root canal treatment.<sup>7,8,9,11</sup>

The intracanal medication has the function of eliminate remaining microorganisms and prevent recontamination, prevent or reduce periapical inflammation, solubilize organic matter, neutralize toxins, control persistent exudation, control external inflammatory resorption and stimulate repair.<sup>7,8,9</sup> Calcium hydroxide is the most appropriate medication for endodontic purposes, being a substance with antimicrobial activity, inhibiting root resorption and inducing formation of hard tissue. However it is necessary a long time in contact with the tissue so that its action is successful,<sup>5-9,13,17</sup> which justified the permanence of calcium hydroxide inside the canals for a month in this case presented.



**Figure 5.** Radiographic control of endodontic treatment after 2 years, with appearance of normality.

The biological purpose of root canal filling is to provide favorable conditions for the body to repair tissue with no risk of relapse<sup>3,7,8,9</sup> and the used calcium hydroxide-based sealer (Sealer 26®) seems to achieve this goal<sup>3</sup> (Fig 4). In the case reported, the repair could be confirmed in the control radiograph, two years after completion of endodontic treatment (Fig 5).

## Conclusions

Changes in shape and number of roots and root canals are likely to occur, and sometimes in a rare form, as in the premolar with three roots and three canals. Thus the professional is required to pay more attention to the diagnostic radiographs during the course of endodontic treatment, so such alterations do not affect prognosis.

## References

1. Atieh MA. Root and canal morphology of maxillary first premolars in a Saudi population. *J Contemp Dent Pract.* 2008;9(1):46-53.
2. Bellizzi R, Hartwell G. Evaluating the maxillary premolar with three canals for endodontic therapy. *J Endod.* 1981; 7(11):521-7.
3. Bernardes RA, Campelo AA, Silva Junior D, Pereira LO, Duarte MA, Moraes IG, Bramante CM. Evaluation of the flow rate of 3 endodontic sealers: Sealer 26, AH Plus, and MTA Obtura. *Oral Surg Oral Med Oral Pathol Oral Radiol Endod.* 2010;109(1):e47-9.
4. Chaparro AJ, Segura JJ, Guerrero E, Jiménez-Rubio A, Murillo C, Feito JJ. Number of roots and canals in maxillary first premolars: study of an Andalusian population. *Endod Dent Traumatol.* 1999;15(2):65-7.
5. Hauman CHJ, Love RM. Biocompatibility of dental materials used in contemporary endodontic therapy: a review. Part 1. Intracanal drugs and substances. *Int Endod J.* 2003;36(2):75-85.
6. Kawashima N, Wadachi R, Suda H, Yeng T, Parashos P. Root canal medicaments. *Int Dent J.* 2009;59(1):5-11.
7. Lauretti MB, Isaac APMAS. Manual de técnica endodôntica. São Paulo: Ed. Santos; 2005. 219 p.
8. Leonardo MR. Endodontia: tratamento de canais radiculares: princípios técnicos e biológicos. São Paulo: Artes Médicas; 2005. 1491 p.
9. Lopes HP, Siqueira Jr JF. Endodontia, Biologia e técnica. Rio de Janeiro: Guanabara Koogan; 2004. 964 p.
10. López FU, Travessas JA, Fachin E, Fontanella V, Grecca F. Apical transportation: two assessment methods. *Aust Endod J.* 2009;35(2):85-8.
11. Martins RC, Bahia MG, Buono VT. Geometric and dimensional characteristics of simulated curved canals prepared with ProTaper instruments. *J Appl Oral Sci.* 2010;18(1):44-9.
12. Mattuella LG, Mazzocato G, Vier FV, Sô MVR. Root canals and apical foramina of the buccal root of maxillary first premolars with longitudinal sulcus. *Braz Dent J.* 2005;16(1):23-9.
13. Mohammadi Z, Abbott PV. Antimicrobial substantivity of root canal irrigants and medicaments: a review. *Aust Endod J.* 2009;35(3):131-9.
14. Nahmias Y, Rampado ME. Root-canal treatment of trifid crown premolar. *Int Endod J.* 2002;35(4):390-4.
15. Pécora JD, Saquy PC, Souza Neto MD, Woelfel JB. Root form and canal anatomy of maxillary first premolars. *Braz Dent J.* 1991;2:87-94.
16. Rózylo TK, Miazek M, Rózylo-Kalinowska I, Burdan F. Morphology of root canals in adult premolar teeth. *Folia Morphol (Warsz).* 2008;67(4):280-5.
17. Siqueira Jr JF, Lopes HP. Mechanisms of antimicrobial activity of calcium hydroxide: a critical review. *Int Endod J.* 1999;32(5):361-9.
18. Soares JA, Leonardo RT. Root canal treatment of three-rooted maxillary first and second premolars – a case report. *Int Endod J.* 2003;36(10):705-10.
19. Vertucci FJ, Gegauff A. Root canal morphology of the maxillary first premolar. *J Am Dent Assoc.* 1979;99(2):194-8.
20. Woodmansey KF. Endodontic treatment of three-rooted maxillary first premolar: a case report. *Gen Dent.* 2006;54(6):420-4.