

# Maxillary sinus disease of odontogenic origin

Priscila Dias **PEYNEAU**<sup>1</sup>

Lívia Gravina Teixeira de **OLIVEIRA**<sup>2</sup>

Pollyanna Moura Rodrigues **CARNEIRO**<sup>3</sup>

Flavio Ricardo **MANZI**<sup>4</sup>

## ABSTRACT

**Introduction:** Due to the intimate relationship between the root apices of maxillary posterior teeth and the maxillary sinus, in some cases, maxillary sinusitis may be of odontogenic origin, such as tooth extractions, periodontal and periapical lesions (abscesses, granulomas and root cysts). Computerized tomography

is the exam of choice to help with the diagnosis of sinusopathies. **Objective:** The aim of this study was to assess the aspects that characterize an odontogenic sinusitis by means of a case report.

**Keywords:** Maxillary sinus. Dental infection. Oral diagnosis. Maxillary sinusitis.

**How to cite this article:** Peyneau PD, Oliveira LGT, Carneiro PMR, Manzi FR. Maxillary sinus disease of odontogenic origin. *Dental Press Endod.* 2013 May-Aug;3(2):80-3.

» The authors report no commercial, proprietary or financial interest in the products or companies described in this article.

<sup>1</sup>MSc in Dentistry, Catholic University of Minas Gerais (PUC-Minas).

<sup>2</sup>Graduated in Dentistry, PUC-Minas.

<sup>3</sup>MSc in Clinical Dentistry, PUC-Minas.

<sup>4</sup>Postdoc in Dental Radiology, State University of Campinas (UNICAMP). Professor Dental Radiology at PUC-Minas.

» The patient displayed in this article previously approved the use of her facial and intraoral photographs.

Received: July 1, 2013. Accepted: August 23, 2013.

Contact address: Flávio Ricardo Manzi  
Av. Dom José Gaspar, Prédio 45 – Clínica de Radiologia  
Coração Eucarístico, Belo Horizonte/MG — Brazil – CEP: 30535-901  
E-mail: manzi@pucminas.br

## Introduction

Inflammatory sinusopathy has been considered the most prevalent chronic disease in all age groups and the fifth major cause of the use of antibiotics. The occurrence of acute, recurrent inflammatory sinusopathies and chronic inflammatory sinusopathies in children in the age-range between one and seven years may be considered frequent. Sinusitis may develop as a result of sinus membrane inflammation, as a consequence of infectious systemic diseases or general diseases of the body, such as colds, influenza, measles, pneumonia, among others. Sinus inflammation may also occur through the spread of an infectious focus of odontogenic origin.

Another factor that may contribute to the development of sinusopathies, mainly those of chronic nature, is the consequence of periapical lesions established in a non-vital tooth, with an infectious process, which may promote the occurrence of oroantral fistulas.<sup>1</sup> Another odontogenic infection that may disseminate itself and lead to a sinusopathy arise from endoperiodontal lesions characterized by the association of periodontal and pulp disease in one and the same tooth, thus, once again, the proximity of the teeth to the sinus will cause the infection to be disseminated.<sup>1-5</sup>

Odontogenic sinusitis comprises from 10 to 12% of maxillary sinus. The odontogenic origin of sinusitis must be considered in patients with a history of odontogenic, dentosurgical-alveolar or periodontal infection. Approximately one tenth of all sinusitis cases corresponds to maxillary sinusitis, not only due to the proximity between the maxillary sinus and the maxillary teeth, but also for being more susceptible to invasion by pathogenic microorganisms.

It is important to make an in-depth analysis to determine whether the sinus disease is of odontogenic origin or not. Diagnosing sinus disease of odontogenic origin demands complete clinical and radiographic evaluation, with special attention paid to the patient's history and symptomatology, which include headache, maxillary sensitivity and nasal congestion.

Computerized tomography is the exam of choice of help with the diagnosis of sinusopathies, as it allows visualization of the main sinus cavity, sinus floor, all of its walls as well as the roof or superior border. Additionally, it not only allows a comparison of both sides and of hard and soft tissues images, but also the identification

of the exact location of the lesion and eventual defects in the sinus wall. Thus, information is more precise.<sup>1-3,7</sup>

The aim of this study was to report a clinical case of a sinusopathy of odontogenic origin, showing clinical and tomographic information, classifying this pathological condition and forms of treatment.

## Case report

A 56-year-old female patient sought an otorhinolaryngologist with the chief complaint of internal pressure, sensation of a heavy head on her right side, and difficulty breathing through the right nostril, with a history of recurrent sinusitis. After antibiotic therapy, there was no remission of symptoms. The professional suspected sinusitis of odontogenic origin. When questioned, the patient reported an episode of a bitter taste in the mouth.

Computerized tomography was performed in a volumetric tomograph, and coronal axial and sagittal reconstructions with thickness and interval of 5 mm were obtained. In addition, panoramic and transverse reconstructions were performed in the region of the maxillary posterior teeth on the right side, with thickness and interval of 1 mm.

In the CT exam, material of density of soft parts (opacification/concealment) were observed, occupying practically the entire right maxillary sinus, extending to the main drainage infundibulum of the sinus which was obliterated. Some anterior ethmoidal cells on the right side presented mucosal and/or partially concealed thickening, with normal intercellular septum. The frontal sinus on this side was also concealed. The frontonasal and sphenoidal recesses on the right side were obliterated. The other paranasal sinuses, as well as their outlines and drainage tracts, were normal. Furthermore, hyperplastic increase in the inferior nasal horn on the right side was observed, diminishing the nasal airway on this side, in addition to nasal septum deviation with convexity facing the left side.

In the panoramic, transverse (Fig 1) and coronal reconstructions, bone rarefaction was observed in the periapical and furca region of tooth 16, with endodontic treatment, compatible with osteolytic lesion of inflammatory/infectious origin. This process promoted discontinuity of the vestibular cortical of the alveolar process and maxillary sinus floor, resulting in dissemi-

nation of this condition to the paranasal sinuses on the right side. Thus, it could be concluded that this chronic, recurrent sinusitis was of odontogenic origin.

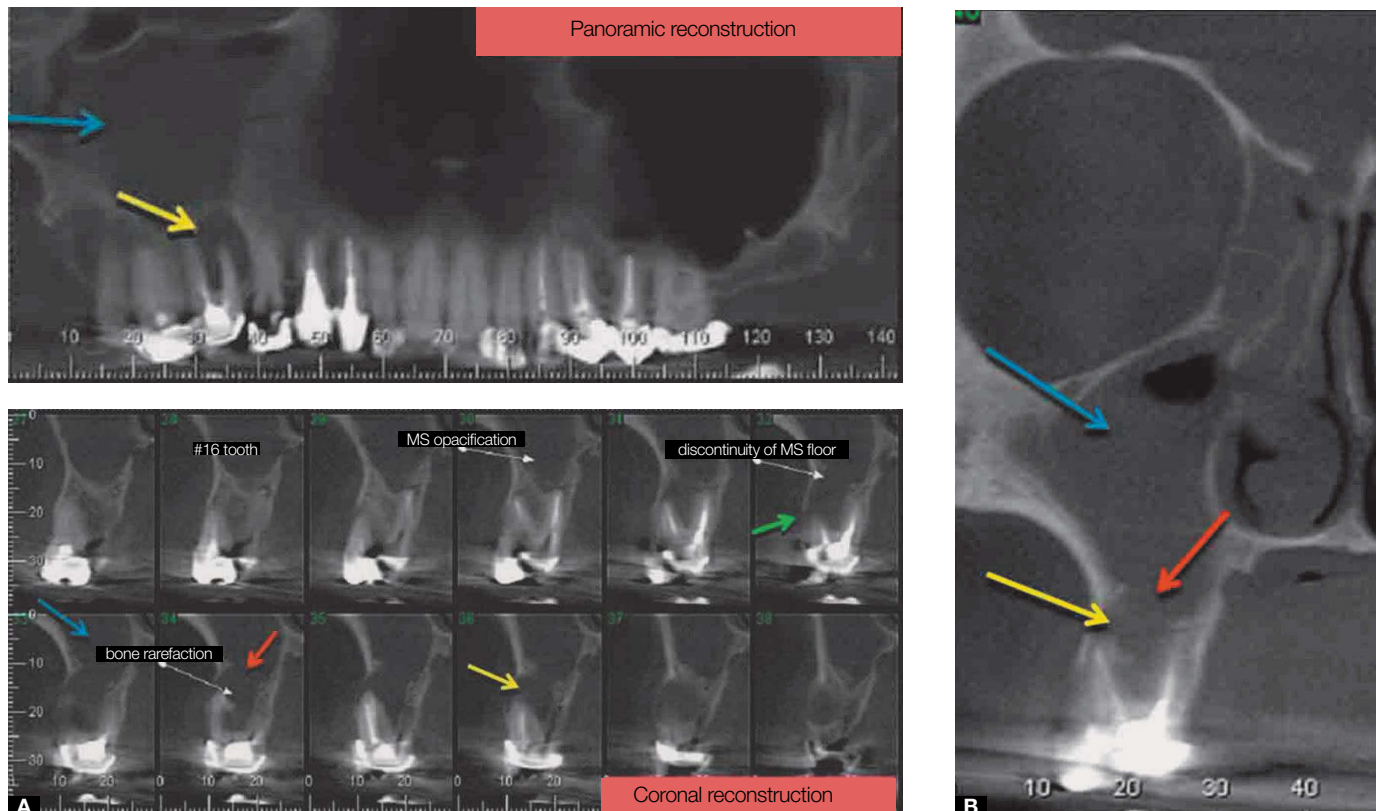
The treatment proposed was extraction of #16 with remission of the chronic sinusopathy condition. New CT was requested for control.

### Discussion

Odontogenic sinusitis is a pathological condition frequently underestimated, and in which tooth infections are responsible for 5% to 10% of maxillary sinusitis cases. In chronic odontogenic sinusitis, asymptomatic development or the presentation of few symptoms is frequently observed, including headaches that increase when moving the head and drainage of secretions through the nasal cavity. Resolution of cases with these characteristics depends on the combination of treatments carried out by doctors and dentists.<sup>1</sup>

An in-depth analysis is important to determine whether the sinus disease is of odontogenic origin or not. Diagnosing sinus disease of odontogenic origin demands complete clinical and radiographic evaluation, with special attention paid to the patient's history and symptomatology, which include headache, maxillary sensitivity and nasal congestion.<sup>2</sup>

Computerized tomography is one of the main complementary exams that help professionals with the diagnosis of a sinusitis of odontogenic origin. This will be requested by the otorhinolaryngologist when the cause of a sinus disease is unknown, or when there is no remission of the symptoms.<sup>2,8</sup> It is extremely important to have interdisciplinary relationships between the dentist, the otorhinolaryngologist and the radiologist doctors, so that procedures can be correctly performed, thus, leading to adequate diagnosis and treatment of the case.



**Figure 1.** A) Panoramic reconstruction and cross section: Note bone rarefaction in the periapical and furca region of #16 tooth, compatible with osteolytic lesion of inflammatory/infectious origin. B) Coronal reconstruction: discontinuity of the vestibular cortical of the alveolar process and maxillary sinus (MS) floor.

The treatment proposed to the patient was removal of the cause, which was tooth 16, and a new CT for control. The resolution of cases with these characteristics depends on the combination of medical and dental treatments, bearing in mind that the patient sought the dentist after having been evaluated by an otorhinolaryngologist and referred by the latter to another professional for evaluation. In this case, the dentist participated in the diagnosis, detecting the tooth that was causing the sinusopathy, and, using his professional skills, took care to have it treated or removed, directly acting on the origin of the problem.

## Conclusion

It is important to point out that the CT is one of the main complementary exams that help professionals in the diagnosis of a sinusitis of odontogenic origin, and is requested by the otorhinolaryngologist when the cause of a sinus disease is unknown, or when there is no remission of the symptoms after antibiotic therapy. Nevertheless, it is extremely important to have an interdisciplinary relationship between the dentist and the otorhinolaryngologist, so that procedures are correctly performed, which leads to adequate diagnosis and treatment of the case.

## References

- 1 Nair UP, Nair M K. Maxillary sinusitis of odontogenic origin: cone-beam volumetric computerized tomography-aided diagnosis. *Oral Surg Oral Med Oral Pathol Oral Radiol Endod.* 2010;110(6):e53-7.
- 2 Mehra P, Murad H. Maxillary sinus disease of odontogenic origin. *Otolaryngol Clin North Am.* 2004;37(2):347-64.
- 3 Abrahams JJ, Glassberg RM. Dental disease: a frequently unrecognized cause of maxillary sinus abnormalities? *Am J Roentgenol.* 1996;166(5):1219-23.
- 4 Mehra P, Jeong D. Maxillary sinusitis of odontogenic origin. *Curr Infect Dis Resp.* 2008;10(3):205-10.
- 5 Brook I. Sinusitis of odontogenic origin. *Otolaryngol Head Neck Surg.* 2006;135(3):349-55.
- 6 Costa F, Emanuelli E, Robiony M, Zerman N, Polini F, Politi M. Endoscopic surgical treatment of chronic maxillary sinusitis of dental origin. *J Oral Maxillofac Surg.* 2007;65(2):223-8.
- 7 Maillet M, Bowles WR, McClanahan SL, John MT, Ahmad M. Cone-beam Computed Tomography evaluation of maxillary sinusitis. *J Endod.* 2011;37(6):753-7.
- 8 Mehra P, Jeong D. Maxillary sinusitis of odontogenic origin. *Curr Infect Dis Rep.* 2008;10(3):205-10.