

# The use of MTA in the treatment of cervical root perforation: case report

Jefferson J. C. **MARION**<sup>1</sup>

Thaís Mageste **DUQUE**<sup>2</sup>

Tatiane Silveira **SANTOS**<sup>3</sup>

Frederico Campos **MANHÃES**<sup>4</sup>

## ABSTRACT

**Objective:** The aim of this study was to report the treatment of a tooth with cervical root perforation caused during endodontic treatment. **Methods:** The patient attended the endodontist's office with painful symptoms resulting from a cervical root perforation exposed to the oral cavity. The endodontic treatment was performed in multiple sessions using the dressing with calcium hydroxide and propylene glycol, in order to aid the decontamination of the root canal and the perforation. The root

perforation was sealed with MTA because this material is capable of forming mineralized tissue due to its sealing ability, biocompatibility and alkalinity. In addition, the humidity present in the periodontal tissues can provide the necessary means to adapt the MTA on the walls of the perforation and its setting expansion, justifying its use in this case as it is a case of cervical perforation, a difficult site to control humidity. **Conclusion:** The authors concluded that MTA is an excellent material for sealing cervical root perforation.

**Keywords:** Root perforation. MTA. Calcium hydroxide.

**How to cite this article:** Marion JJC, Duque TM, Santos TS, Manhães FC. The use of MTA in the treatment of cervical root perforation: case report. *Dental Press Endod.* 2013 May-Aug;3(2):96-101.

» The authors report no commercial, proprietary or financial interest in the products or companies described in this article.

» The patient displayed in this article previously approved the use of her facial and intraoral photographs.

<sup>1</sup>Doctorate student in Dental Clinic – Endodontics, State University of Campinas (UNICAMP). Professor at the Department of Endodontics of ABOI and Ingá College (UNINGÁ).

<sup>2</sup>Doctorate student in Dental Clinic – Endodontics, UNICAMP.

<sup>3</sup>Graduated in Dentistry, UNINGÁ.

<sup>4</sup>Doctorate student in Dental Clinic – Endodontics UNICAMP.

Received: March 12, 2013. Accepted: April 9, 2013.

Contact address: Jefferson José de Carvalho Marion  
Rua Néo Alves Martins, 3176 – 6º andar – sala 64 – Centro  
CEP: 87.013-060 – Maringá/PR – Brazil  
Email: jefferson@jmarion.com.br / atendimento@jmarion.com.br

## Introduction

Root perforation is an accident in which an artificial opening is made, communicating the pulp chamber, the root canals and the periapical tissues. These accidents usually occur due to iatrogenic causes including lack of knowledge of dental anatomy, calcification of the coronary and cervical thirds, failure in radiographic analysis, accentuated and misdirected abrasion as well as lack of pre bending of files in case of curved canals. Pathologies such as cavities, internal and external resorption are factors that can also lead to such accidents.

Among the factors that affect root perforation prognosis are the location (cervical, middle and apical thirds), the extent, presence or absence of periodontal pockets, the time between perforation and treatment, biological compatibility and sealing ability of the filling material.<sup>1</sup>

The faster the perforation is sealed, the more favorable is the prognosis, especially when it involves the cervical third and the pulp chamber. In this site, because it is closer to the oral cavity, bacterial contamination becomes easier and may establish an infection at the site, resulting in tooth loss if the repair is not quickly performed. However, for the middle and apical third of the root, immediate sealing is not necessary if the area is adequately protected from bacterial infiltration.<sup>2</sup>

Perforation can be diagnosed not only by sudden onset of bleeding in the root canal or its persistence after the pulp tissue was removed, but also by clinical exploration, radiographic features showing the file in the periodontium, examination of lateral lesion and pin placed outside the long axis of the root.<sup>1</sup>

For proper treatment, the perforation must be sealed with a biocompatible material, capable of producing a good seal with good physical properties, radiopaque, non-resorbable, easy to use and capable of promoting osteogenesis and cementogenesis.<sup>3</sup>

Given the quality and limitations of the materials routinely used for the sealing of dental perforations, other materials with characteristics that are similar to the ideal sealing have been sought. With the purpose of filling these gaps and based on the technological evolution of new materials, emerged in the 90s at the University of Loma Linda, California - USA, headed by Professor Torabinejad, a group that developed a new cement called Mineral Trioxide Aggregate (MTA).

Since then, several studies have been conducted with this material, analyzing its biocompatibility,<sup>4,5,6,7</sup> its physical, chemical and antimicrobial<sup>7</sup> properties, cytotoxicity,<sup>8</sup> mutagenicity,<sup>9</sup> pulp capping,<sup>10,11</sup> analysis of its sealing ability in retrograde fillings,<sup>12,13</sup> marginal adaptation in Scanning Electron Microscopy (SEM), and their use in root perforations.<sup>14-17</sup>

Still on the applications of MTA, it is also indicated in cases of dental pulp conservative treatment,<sup>10,15,18</sup> apixigenesis and apexification treatments<sup>19</sup> as sealing material to repair perforations resulting from communicating internal and external resorptions,<sup>20</sup> as filling material for root canals of deciduous teeth<sup>21</sup> and permanent teeth,<sup>4,15,22</sup> as repair material for vertical and horizontal root fractures<sup>20</sup>, and as apical plug.

The ability of MTA to form mineralized tissue can be attributed to its sealing ability, biocompatibility, alkalinity or even other properties associated with it.<sup>20</sup>

The aim of the present study is to report the treatment of a tooth with cervical radicular perforation caused during endodontic treatment and sealed with MTA. In addition, it aims at highlighting the advantages and disadvantages of employing and including this material in the sealing of the perforation and also in the maintenance of the dental element in the oral cavity, performing its esthetic and masticatory functions.

## Case report

A 19-year-old patient was referred for endodontic treatment of #43, in June, 2010. During the anamnesis, we found that there was no history of systemic disease, but the patient reported being allergic to Paracetamol. With regard to her dental history, the patient reported being under orthodontic treatment, and that, due to a leakage in the restoration of #43, the patient was referred to a Dental Surgeon (DS) in order to have the restoration exchanged. When the dentist started the restorative procedure, he informed the patient that, due to the depth of the restoration, there had been pulp exposure and, as a result, endodontic treatment would be necessary. After treatment had started, a perforation in the lateral root occurred in an attempt to find the root canal. From this time on, the patient was referred to an endodontist who would seal the perforation and perform root canal treatment.

During the intraoral clinical examination, it was observed that #43 tooth presented open access cavity

without temporary restoration or endodontic dressing, and with remaining carious tissue. In addition, it showed sensitivity to vertical and horizontal percussion and absence of edema, sinus and tooth mobility. As for the thermic tests performed to check pulpal sensitivity, the responses were also negative.

The periapical intraoral radiographic revealed excessive abrasion in the opening and in the cervical portion. Mesially, it was possible to see the path of the perforation. The image also had a radiopaque, non-root, suggestive point indicating some type of restorative material (Fig 1A). After all tests and clinical examinations had been performed, the patient was diagnosed with pulp necrosis.

The patient was informed about the different treatment options, for both perforation and root canal. She chose to undergo endodontic treatment with closure of perforation being performed via the canal, preferably without surgery and application of intracanal medication. It was requested that the orthodontist discontinued the application of orthodontic force in this dental element until the end of the endodontic treatment.

From this moment on, the endodontic treatment began, with local anesthesia and installation of rubber dam. Improvements in the access cavity and removal of carious tissue were carried out with a low-speed bur. Biomechanical preparation of the root canal was performed with manual endodontic files and irrigated with sodium hypochlorite at 2.5%. During the biomechanical preparation of the root canal, odontometry confirmation of the length of work and the apical patency were carried out (Fig 1B). After biomechanical preparation of the root canal, it was dried with sterile paper points and then flooded with trisodium EDTA at 17% for 3 minutes, with manual shaking for better cleaning of the canal. After this period, the EDTA was removed and new irrigation was performed with sodium hypochlorite, followed by further drying of the root canal. Afterwards, a calcium-hydroxide-based intracanal medication with propylene glycol was applied in order to help in the decontamination of the root canal and of the perforation.

After 15 days, the intracanal medication was removed with the purpose of closing the perforation. The material chosen for final closure of the perforation was the white MTA-Angelus, manipulated accord-

ing to the manufacturer's instructions. The MTA was inserted with Paiva pressers and its final laying was carried out with cotton moistened with distilled water. The MTA was inserted into the perforation with the aid of a microscope and without exerting too much pressure in order to prevent it from extravasating to the periodontal ligament.

An intraoral periapical radiograph was performed to check the MTA laying in the perforation. Radiographically, it was observed that the MTA did not extravasate to the periodontal ligament, momentarily excluding the possibility of surgical intervention for the case (Fig 1C).

The calcium-hydroxide-based intracanal medication was applied for a period of three months and replaced every 45 days. After a period of four months (October, 2010), the root canal was filled with gutta-percha point (Fig 2A) and, afterwards, with calcium-hydroxide-based cement and secondary gutta-percha points by lateral condensation followed by means of the vertical condensation technique (Fig 2B). The pulp chamber was cleaned and temporarily sealed with sterile cotton pellet and Coltosol. The patient was asked to seek his dentist in order to request that definitive restorative procedures were performed.

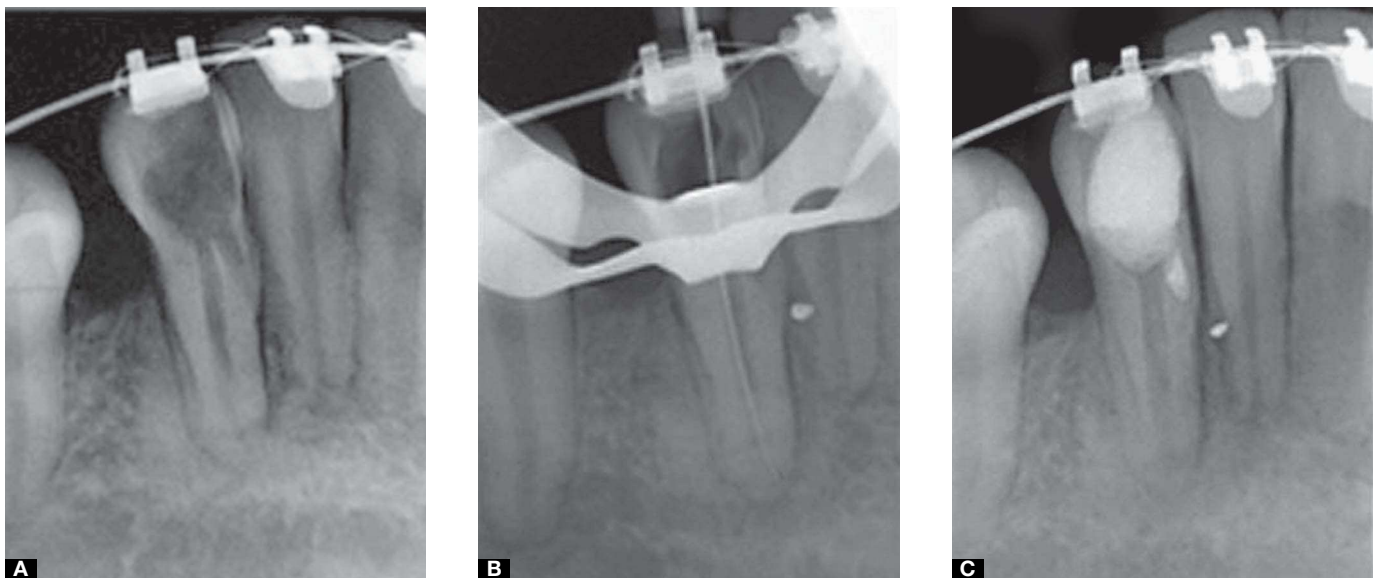
Figure 2B shows the root canal filling, closure of perforation with MTA and, in the mesial apical portion, a secondary canal filling which was possible to be seen in Figure 2A.

After 10 months of endodontic treatment, the patient was asked to have the first follow up radiograph. In the intraoral periapical radiograph, it was possible to observe the integrity of the periapical region with continuous lamina dura clinically indicating periapical repair (Fig 2C).

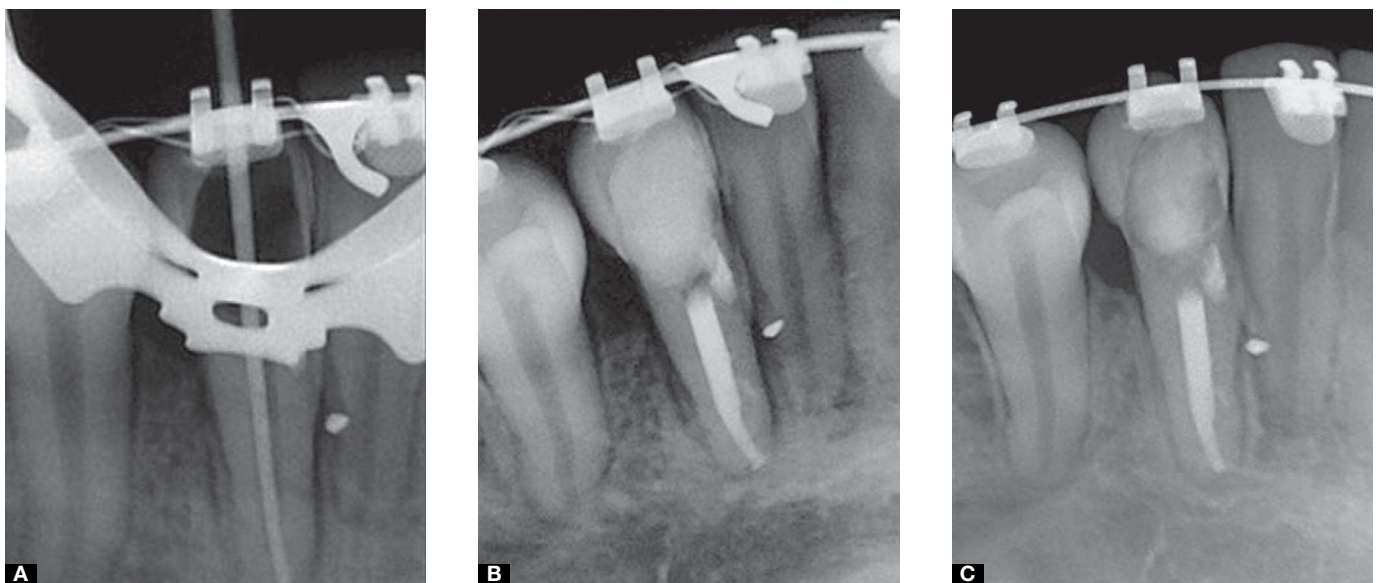
## Discussion

The success of nonsurgical root perforation procedures is directly related to the severity of the initial damage caused to the periodontal tissue, the size and location of the perforation, sealing ability and biocompatibility of the filling material, and the presence or absence of bacterial contamination.<sup>23</sup>

In this case report, the cervical perforation was not sealed immediately after it had occurred, as suggested by Sinai<sup>2</sup> and Pitt Ford et al.<sup>13</sup> The authors claim that the prognosis is much more favorable in



**Figure 1.** A) Initial radiograph: Excessive coronary abrasion, perforation path to mesial and radiopaque extraradicular point suggesting restorative material. B) Confirmation of the working length. C) Setting of the MTA in the perforation.



**Figure 2.** A) Master cone and presence of accessory mesial canal. B) Final radiograph. C) 10-month follow up.

this case due to lack of bacterial contamination. There was the option of treating the perforation and the root canal by means of exchanging the intracanal medication and irrigating the site with sodium hypochlorite, since the pulp chamber and the root canal were exposed to the oral cavity. Thus, based on the studies carried out by Estrela and Estrela<sup>1</sup> who claim that fighting bacterial infection through copious irrigation with sodium hypochlorite solution, due to its organic material and antibacterial solvent properties,

completes the sanitation promoted by biomechanical preparation. Applying the calcium-hydroxide-based intracanal medication with propylene glycol, between sessions, in order to supplement disinfection and/or deposition of mineralized tissue through its antiseptic effect, bactericidal action and high pH, corroborate Holland et al<sup>24</sup>, Holland et al.<sup>25,26</sup>

Estrela and Estrela<sup>1</sup> have stated that there is inactivation of enzymes intra and extra-cellular due to the release of hydroxyl ions, which hinders bacterial survival.

However, studies carried out by Felipe et al<sup>27</sup> claim that there is no advantage in exchanging the calcium hydroxide paste when treating contaminated canals and pulpless teeth.

The choice of propylene glycol as a carrier for the calcium hydroxide is based on studies carried out by O'Neil<sup>28</sup> which demonstrate that the substance has a great capacity to solubilize organic materials. Additionally, Seidenfeld and Hanzlik<sup>29</sup> claim that the propylene glycol has approximately the same density of water and causes no demonstrable cumulative effect.

The propylene glycol antimicrobial activity for systemic use has been studied by Olitzky<sup>30</sup> who reported that concentrated solutions of this compound have demonstrated germicidal efficiency and its use as a carrier can work in the prevention or treatment of bacterial infection. Walkevar, Bhat;<sup>31</sup> Thomas, Kotian and Bath<sup>32</sup> reported that in addition to the fact that propylene glycol has been well recognized as a carrier for medications, it has also been considered to be less cytotoxic than other carriers commonly used for intracanal medications. Moreover, it presents antibacterial properties highly beneficial in endodontic treatment, although the results found by Nakayama and Safavi<sup>33</sup> showed that calcium hydroxide does not dissociate from propylene glycol because it needs water to be dissociated.

In order to remove the smear layer, the EDTA at 17% was used for 3 minutes before the intracanal medication was applied in all sessions as well as before final filling of the root canal, since several studies have demonstrated that removal is achieved with the use of this drug.<sup>34,35</sup>

After 15 days, the root perforation closure was performed with MTA because, according to Torabinejad and Chivian,<sup>20</sup> this material is capable of forming mineralized tissue due to its sealing ability, biocompatibility, and alkalinity. Furthermore, according to Sluyk et al<sup>17</sup> the humidity present in periodontal tissues can provide the necessary means for adaptation of MTA on the walls of the perforation and also for setting expansion,<sup>20,36</sup> which explains its use in this case report, a case of cervical perforation in which humidity is difficult to control.

In this case, MTA was also used because its radiopacity is superior to that of the dentin and bone tissue, the IRM, Super Eba and gutta-percha, thus, providing diagnostic observation, which makes it the material of choice.<sup>6</sup> Moreover, studies carried out by Holland et al,<sup>26</sup> of which aim was to explain the mechanism of inducing mineral formation of MTA, found that MTA without calcium hydroxide in its composition is capable of forming mineralized tissue due to the presence of calcium oxide which forms calcium hydroxide when reacted with periapical tissues.

The authors of this study agree with Marion<sup>37</sup> about the difficulties of working with MTA and aqueous carrier (distilled water) together, due to its initial setting time and also its difficulty to be inserted, because when MTA is handled with this carrier, it seems to be little bondable and sandy.

According to Namazikhah,<sup>38</sup> it is important to emphasize that when the MTA is used in environments with inflammation, its physicochemical properties may suffer some interferences, causing its acid pH to prevent the MTA setting and reduce its strength and hardness. However, once the factors that initiate or perpetuate the inflammatory process have been removed, as in the case presented, the environment is able to return to normality within a short period of time.

Despite the advantages and limitations of the MTA, which have been previously mentioned, studies carried out by Balto,<sup>39</sup> Holland et al,<sup>11</sup> Juárez Broon et al,<sup>3</sup> showed that when analyzing the biological behavior of materials used in sealing root perforations, the MTA has shown similar or less toxic behavior than the others. Therefore, MTA proves to have great ability of repair and the aforementioned information explains its use in the treatment of cervical root perforations.

## Conclusion

After being clinically applied, the MTA proved to be effective as a filling material of cervical root perforation, since after a 10-month follow-up, the tooth continued to perform its primary functions, esthetic and masticatory, in the oral cavity.



## References

- Estrela C, Estrela CRA. O hidróxido de cálcio é a única medicação intracanal para combater a infecção endodôntica? In: Cardoso RJA, Gonçalves EAN. Endodontia e trauma. São Paulo: Artes Médicas; 2002. p. 239-66.
- Sinai IH. Endodontic perforations: their prognosis and treatment. *J Am Dent Assoc.* 1977;95(1):90-5.
- Juárez Broon N, Bramante CM, Assis GF, Bortoluzzi EA, Bernardinelli N, Moraes IG, et al. Healing of root perforations treated with mineral trioxide aggregate (MTA) and Portland cement. *J Appl Oral Sci.* 2006;14(5):305-11.
- Holland R, Souza V, Nery MJ, Otoboni Filho JA, Bernabé PFE, Dezan Júnior E. Reaction of dogs' teeth to root canal filling with mineral trioxide aggregate or a glass ionomer sealer. *J Endod.* 1999;25(11):728-30.
- Holland R, Souza V, Nery MJ, Faraco Júnior IM, Bernabé PFE, Otoboni Filho JA, et al. Reaction of rat connective tissue to implanted dentin tube filled with mineral trioxide aggregate, Portland cement or calcium hydroxide. *Braz Dent J.* 2001;12(1):3-8.
- Torabinejad M, Hong CU, Lee SJ, Monsef M, Ford TR. Investigation of mineral trioxide aggregate for root-end filling in dogs. *J Endod.* 1995;21(12):603-7.
- Torabinejad M, Hong CU, Pitt Ford TR, Kaiyawasam SP. Tissue reaction to implant Super-EBA and Mineral Trioxide Aggregate in the mandible of guinea pigs: a preliminary report. *J Endod.* 1995;21(11):569-71.
- Torabinejad M, Hong CU, Pitt Ford TR, Kettering JD. Cytotoxicity of four root end filling materials. *J Endod.* 1995;21(10):489-92.
- Kettering JD, Torabinejad M. Investigation of mutagenicity of mineral trioxide aggregate and other commonly used root-end filling materials. *J Endod.* 1995;21(11):537-9.
- Faraco Júnior IM, Holland R. Histomorphological response of dogs' dental pulp capped with white mineral trioxide aggregate. *Braz Dent J.* 2004;15(2):104-8.
- Holland R, Filho JA, Souza V, Nery MJ, Bernabé PF, Dezan Júnior E. Mineral trioxide aggregate repair of lateral root perforations. *J Endod.* 2001;27(4):281-4.
- Scheerer SQ, Steiman HR, Cohen J. A comparative evaluation of three root-end filling materials: an in vitro leakage study using *Prevotella nigrescens*. *J Endod.* 2001;27(1):40-2.
- Torabinejad M, Rastegar AF, Kettering JD, Pitt Ford TR. Bacterial leakage of mineral trioxide aggregate as a root end filling material. *J Endod.* 1995;21(3):109-12.
- Arens DE, Torabinejad M. Repair of furcal perforations with mineral trioxide aggregate: two case reports. *Oral Surg Oral Med Oral Pathol Oral Radiol Endod.* 1996;82(1):84-8.
- Holland R, Souza V, Murata SS, Nery MJ, Bernabé PF, Otoboni Filho JA, Dezan Júnior E. Healing process of dog dental pulp after pulpotomy and pulp covering with mineral trioxide aggregate or Portland cement. *Braz Dent J.* 2001;12(2):109-13.
- Lee SJ, Monsef M, Torabinejad M. Sealing ability of a mineral trioxide aggregate for repair of lateral root perforations. *J Endod.* 1993;19(11):541-4.
- Sluyk SR, Moon PC, Hartwell GR. Evaluation of setting properties and retention characteristics of mineral trioxide aggregate when used as a furcation perforation repair material. *J Endod.* 1998;24(11):768-71.
- Faraco Júnior IM, Holland R. Response of the pulp of dogs to capping with mineral trioxide aggregate or a calcium hydroxide cement. *Endod Dent Traumatol.* 2001;17(4):163-6.
- Shabahang S, Torabinejad M. Treatment of teeth with open apices using mineral trioxide aggregate. *Pract Periodontics Aesthet Dent.* 2000;12(3):315-20; quiz 322.
- Torabinejad M, Chivian N. Clinical applications of mineral trioxide aggregate. *J Endod.* 1999;25(3):197-205.
- O'sullivan SM, Hartwell GR. Obturation of a retained primary mandibular second molar using mineral trioxide aggregate: a case report. *J Endod.* 2001;27(11):703-5.
- Holland R, Mazuqueli L, Souza V, Murata SS, Dezan Junior E, Suzuki P. Influence of the type of vehicle and limit of obturation on apical and periapical tissue response in dogs' teeth after root canal filling with mineral trioxide aggregate. *J Endod.* 2007;33(6):693-7.
- Páttaro ES, Amaral KF, Gavini G. Capacidade selante de materiais restauradores empregados no preenchimento de perfurações de furca. *Rev Odontol Univ Cid São Paulo.* 2004;16(1):47-53.
- Holland R, Souza V, Tagliavini RL, Milanezi LA. Healing process of teeth with open apices. Histological study. *Bull Tokyo Dent Coll.* 1971;12(4):333-8.
- Holland R, Souza V, Nery MJ, Mello W, Bernabé PFE, Otoboni Filho JA. Effect of the dressing in root canal treatment with calcium hydroxide. *Rev Fac Odontol Araçatuba.* 1978;7(1):39-45.
- Holland R, Otoboni Filho JA, Souza V, Nery MJ, Bernabé PFE, Dezan Júnior E. Reparação dos tecidos periapicais com diferentes formulações de Ca(OH)<sub>2</sub>. Estudo em cães. *Rev Assoc Paul Cir Dent.* 1999;53(4):327-31.
- Felippe MCS, Felipe WT, Marques MM, Antoniazzi JH. The effect of renewal of calcium hydroxide paste on the apexification and periapical healing of teeth with incomplete root formation. *Int Endod J.* 2005;38(7):436-42.
- O'Neil MJ, editor. *The Merck index: an encyclopedia of chemicals, drugs and biologicals.* 13a ed. New Jersey: Merck; 2001.
- Seidenfeld MA, Hanzlik PJ. The general properties, actions and toxicity of propylene glycol. *J Pharmacol.* 1932;44:109-21.
- Oltzky I. Antimicrobial properties of a propylene glycol based topical therapeutic agent. *J Pharm Sci.* 1965;54(5):787-8.
- Bhat KS, Walkevar S. Evaluation of bactericidal property of propylene glycol for its possible use in endodontics. *Arogya J Health Sci.* 1975;1(4):54-9.
- Thomas PA, Bath KS, Kotian KM. Antibacterial properties of dilute formocresol and eugenol and propylene glycol. *Oral Surg Oral Med Oral Pathol.* 1980;49(2):166-70.
- Safavi K, Nakayama TA. Influence of mixing vehicle on dissociation of calcium hydroxide in solution. *J Endod.* 2000;26(11):649-51.
- Cengiz T, Aktener BO, Piskin B. The effect of dentinal tubule orientation on the removal of Smear layer by root canal irrigant. A scanning electron microscopic study. *Int Endod J.* 1990;23(3):163-71.
- Meryon SD, Tobias RS, Jakeman KJ. Smear removal agents: a quantitative study in vivo and in vitro. *J Prosthet Dent.* 1987;57(2):174-9.
- Ruiz PA, Souza AHF, Amorim RFB, Carvalho RA. Agregado de trióxido mineral (MTA): uma nova perspectiva em endodontia. *Rev Bras Odontol.* 2003;60(1):33-5.
- Marion JJC. Processo de reparo de dentes de cães após biopulpectomia e obturação dos canais radiculares com os cimentos Sealapex<sup>TM</sup> ou MTA manipulado com propilenoglicol, associados ao efeito do emprego ou não de um curativo de corticosteróide-antibiótico [dissertação]. Marília (SP): Universidade de Marília; 2008.
- Namazikhah MS. The effect of pH on surface hardness and microstructure of mineral trioxide aggregate. *Int Endod J.* 2008;41(2):108-16.
- Balto HA. Attachment and morphological behavior of human periodontal ligament fibroblasts to mineral trioxide aggregate: a scanning electron microscope study. *J Endod.* 2004;30(1):25-9.