

# Endodontic reintervention with ProTaper Universal Retreatment files: a case report

Diesse Moreno **SOUZA**<sup>1</sup>

Rogério Vieira **SILVA**<sup>2</sup>

Renato Piai **PEREIRA**<sup>3</sup>

Eduardo **NUNES**<sup>4</sup>

DOI: <http://dx.doi.org/10.14436/2358-2545.6.1.021-026.cre>

## ABSTRACT

**Introduction:** Chemical-mechanical preparation enables antiseptics of the root canal system by the action of chemical substances, being crucial for therapeutic success. Endodontic reintervention is grounded on a new treatment approach in which the filling material is completely removed before reinstrumentation, antiseptics and adequate filling when previous treatment fails. **Objective:** To report a clinical case of endodontic reintervention on a mandibular first molar on the right side by using ProTaper retreatment instruments. **Methods:** Caucasian male patient was referred to the graduate endodontic clinic of Bahia Dental Association in the city of Vitória da Conquista. Coronal restoration with marginal percolation was revealed by clinical examination. Negative responses to vertical horizontal percussion and palpation were found in the evaluation, including absence of periodontal pocket and soft tissues within

the normality range. Radiographic examination showed poor endodontic restoration and periapical rarefying osteitis. Periapical diagnosis was found to be suggestive of periradicular granuloma, thus indicating endodontic reintervention. In the first visit, biomechanical preparation of the root canals, intracanal medication with  $\text{Ca(OH)}_2$  and double coronal seal with Coltosol and glass ionomer for 21 days were performed. In the second visit, the root canal system was filled. The patient was asymptomatic on clinical and radiographic evaluations after two years within normality range. **Conclusions:** The proposed treatment was proven to be efficient in combating microorganisms present within the root canals. It was possible to observe the therapeutic success in view of both lesion regression and re-establishment of periapical tissues.

**Keywords:** Endodontics. Retreatment. Root canal therapy.

**How to cite this article:** Souza DM, Silva RV, Pereira RP, Nunes E. Endodontic reintervention with ProTaper Universal Retreatment files: a case report. *Dental Press Endod.* 2016 Jan-Apr;6(1):21-6.

DOI: <http://dx.doi.org/10.14436/2358-2545.6.1.021-026.cre>

» The authors report no commercial, proprietary or financial interest in the products or companies described in this article.

» Patients displayed in this article previously approved the use of their facial and intraoral photographs.

<sup>1</sup>Dental surgeon, Faculdade Independente do Nordeste (FAINOR), Vitória da Conquista, Bahia, Brazil.

<sup>2</sup>Assistant professor, Faculdade Independente do Nordeste (FAINOR), Undergraduate Program of Dentistry, Vitória da Conquista, Bahia, Brazil.

<sup>3</sup>Assistant professor, Universidade Estadual do Sudoeste da Bahia (UESB), Undergraduate Program of Dentistry, Itapetinga, Bahia, Brazil.

<sup>4</sup>Adjunct professor, Pontifícia Universidade Católica de Minas Gerais (PUC-MG), Undergraduate Program of Dentistry, Belo Horizonte, Minas Gerais, Brazil.

Submitted: 16/10/2015. Revised and accepted: 16/03/2016.

Contact address: Rogério Vieira Silva  
Faculdade Independente do Nordeste (FAINOR)  
Av. Luís Eduardo Magalhães, 1305, Candeias, Vitória da Conquista-BA, Brazil  
CEP: 45.028-440 - E-mail: roger.endo@hotmail.com

## Introduction

Although endodontic treatment has a high rate of success, several species of microorganisms can penetrate the dentinal tubules, thus favouring the maintenance or emergence of endodontic infection.<sup>1-4</sup> The aim of the endodontic reintervention procedure is to eliminate microbial infection by means of a new endodontic therapy when previous treatment fails.<sup>5</sup>

Chemical-mechanical preparation allows cleaning and antiseptics of the root canals by means of the action of chemical substances, thus being of fundamental importance for a clinically successful therapy. Sodium hypochlorite not only has bactericidal action, but it also enables removal of debris and organic remnants, thus reducing significantly the levels of microorganisms and their by-products, which contributes to the process of repair of periapical tissues.<sup>6</sup>

However, the complex anatomy of the root canal system, with isthmuses and irregularities, makes the action by chemical agents difficult in endodontic procedures.<sup>7</sup> Studies show that the use of ultrasonic equipment has been very efficient, mainly by making the intervention mechanism of chemical substances potent in the chemical-mechanical preparation, as areas of difficult access can be reached, thus promoting greater effectiveness.<sup>8</sup>

With the aim to seek a better therapeutic performance of endodontic reintervention, several manual and rotary techniques have been addressed.<sup>9,10</sup> The ProTaper Retreatment system (Dentsply Maillefer, Ballaigues, Switzerland) has been highlighted because it is easily used and efficient during instrumentation. It comprises three rotary nickel-titanium (NiTi) instruments termed D1, D2 and D3, which have conical tip diameters compatible to each root third, thus providing great efficiency during procedures.<sup>11</sup>

An adequate filling of the root canal system plays a fundamental role in Endodontics. In this sense, thermal gutta-percha has been often used, as this technique allows good adaptation to dentinal walls, thus providing greater efficiency in filling procedures.<sup>12</sup> On the other hand, because of their flowing property, endodontic cements can penetrate irregular cavities and areas inaccessible to instruments, thus proving better sealing and quality of root canal system filling.<sup>13,14</sup> Based on these

assumptions, the present study aimed at reporting a clinical case of endodontic reintervention of tooth #36 by using ProTaper Retreatment rotary files.

## Clinical case report

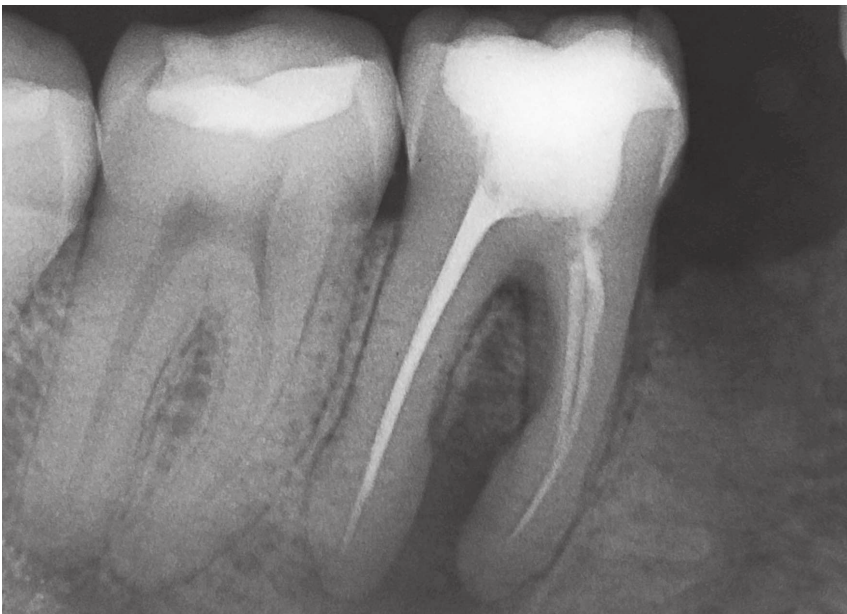Caucasian male patient was referred to the graduate endodontic clinic of Bahia Dental Association in the city of Vitória da Conquista for endodontic evaluation of first mandibular molar on the right side. Clinical examination revealed marginal percolation and great coronal destruction of restoration with light-cured resin. Soft tissues were within normality range, including no pain at vertical/horizontal percussion or palpation at the bottom of the buccal sac, and no periodontal pocket. Radiographic examination showed poor endodontic treatment and loss of periapical bone diffused between the mesial and distal roots (Fig 1). Periapical diagnosis was found to be suggestive of periradicular granuloma, and, therefore, a two-visit treatment was chosen for endodontic reintervention.

In the first visit, the deficient restoration was removed under total isolation, and endodontic access was obtained with a high-speed drill (KG #1558, Medical Burs, Cotia, Brazil). After accessing the pulp chamber, an ultrasonic tip (Enac ST 08, Osada, Tokyo, Japan) was used for preparing the site before gutta-percha removal with orange peel oil, a natural solvent (Lenza Farmacêutica, Belo Horizonte, Brazil), and 5.25% sodium hypochlorite (Lenza Farmacêutica, Belo Horizonte, Brazil) for irrigation. ProTaper Retreatment D1, D2 and D3 rotary files (Maillefer, Ballaigues, Switzerland) were used, complemented with #10 and #15 manual K-files (Maillefer, Ballaigues, Switzerland) for apical foramen patency, ProTaper Universal F1 and F2 files (Maillefer, Ballaigues, Switzerland) for mesial canals and F3 for distal canals. After preparation, the aspect of the pulp chamber floor could be visualized (Fig 2). The apical limit was 1 mm beyond the patency length. The ultrasonic tip (Enac ST 08, Osada, Tokyo, Japan) was activated in association with 17% EDTA (Fórmula & Ação, São Paulo, Brazil) for two minutes in each root canal, with 5.25% sodium hypochlorite being used for final irrigation. The root canals were dried with absorbent paper points before application of

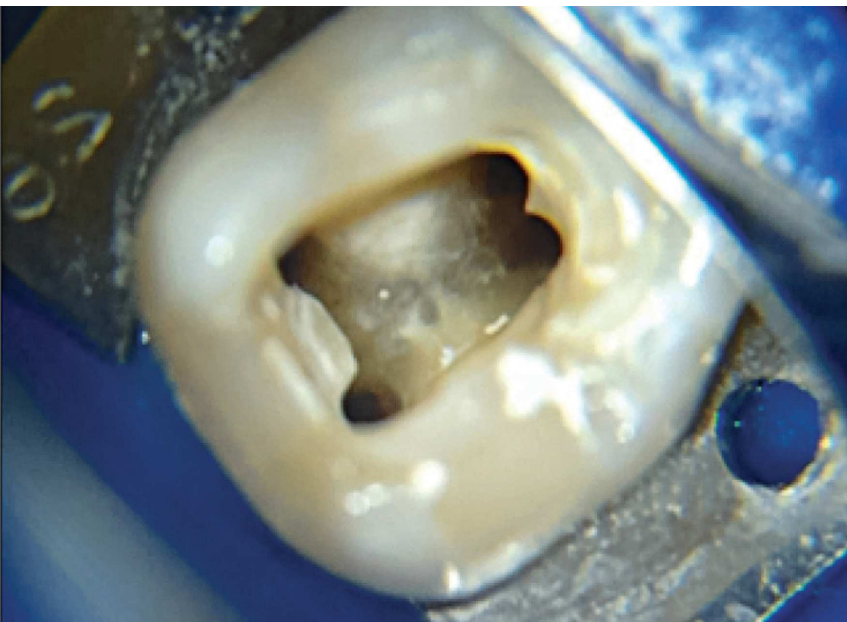
intracanal medication with PA calcium hydroxide (Lenza Farmacêutica, Belo Horizonte, Brazil) and propylene glycol (Lenza Farmacêutica, Belo Horizonte, Brazil). Subsequently, sealing was carried out with Coltosol and glass ionomer for 21 days.

During the second visit, root canals were filled (Fig 3) with the aid of the vertical hydraulic compression of accessory cone<sup>15</sup> with F3 and F2 gutta-percha cones (Maillefer, Ballaigues, Switzerland) for

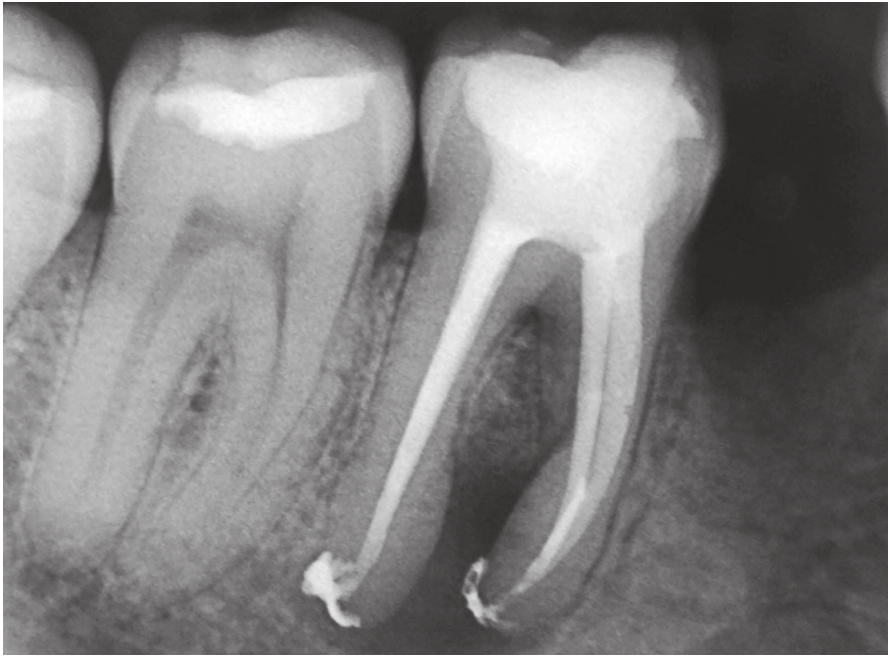distal and mesial root canals, respectively, and endodontic cement (AH Plus, Dentsply, De Trey GmbH, Germany). The case was documented with the aid of an operating microscope (Alliance, São Paulo, Brazil). Follow-up clinical and radiographic examinations (Fig 4) after two years revealed tissue re-establishment and repair of the periapical region, including masticatory and esthetic functions by means of restorative procedure.



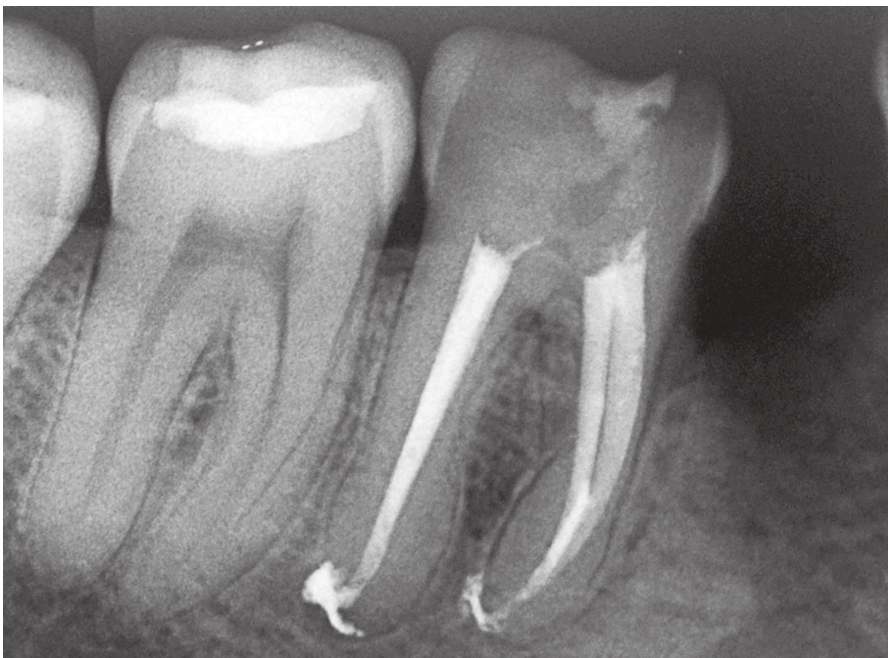**Figure 1.** Preoperative periapical radiograph.



**Figure 2.** Anatomy of pulp chamber floor.



**Figure 3.** Periapical radiographic image of root canal system filling.



**Figure 4.** Periapical radiographic follow-up image two years later.

## Discussion

Although endodontic treatment has a high rate of success, failures may occur, and these are usually associated with poorly performed procedures.<sup>16</sup> In fact, studies have demonstrated that part of the root canal remains often unchanged after chemical-mechanical preparation.<sup>17</sup> These areas can contain both microorganisms and necrotic tissue remnants, even when radiographic examination shows

a seemingly adequate filling.<sup>18</sup> In the present case report, chemical-mechanical preparation had been poorly performed and filling extended beyond the working length, which were probably the causes of failure of previous endodontic therapy.

After a short period of time in contact with microbial factors, the entire root canal system can be recontaminated, regardless of the technique or material used for filling.<sup>19,20</sup> If filling cannot provide a

complete sealing of the root canal, the flow of tissue fluids can favour growth of bacteria to a considerable amount, which can lead to inflammation of periradicular tissues.<sup>21</sup> In accordance with our case report, endodontic reintervention is necessary when previous treatment does not meet the acceptable standards, thus hindering control and prevention of endodontic infection.<sup>22</sup>

One of the main objectives of endodontic retreatment is to remove the filling material completely. This enables a more effective action of instruments and irrigating solutions over the microorganisms and remnants accounting for the process of infection.<sup>23,24</sup> In order to provide a better performance in endodontic reintervention procedures, several methods have been used for filling material removal, including the use of rotary systems developed specifically for such a purpose.<sup>25</sup> The ProTaper Retreatment Rotary System (Maillefer, Ballaigues, Switzerland), used in the present clinical case, was developed to provide greater efficacy in this type of procedure, thus reducing chair time considerably, in comparison to traditional manual instrumentation.<sup>26</sup>

The efficacy of ProTaper Retreatment System was assessed in relation to RaCe NiTi system and stainless manual instruments (i.e., K3 and Hdestroen) in the removal of gutta-percha during endodontic retreatment. ProTaper instruments have significant differences in relation to the other ones, particularly regarding removal of filling material.<sup>27</sup> Its better performance can be attributed to the convex triangular design of instruments and the active cutting tip of D1 instrument, providing more efficient penetration into the cervical third and better removal of gutta-percha. Therefore, this system was indicated for the therapeutic planning of the present case report.

Protaper Retreatment System produced a significantly lower amount of apical debris compared to both Hedstroen and K-flex manual files. This factor may be related to the lower apical pressure of the instrument compared to the manual ones, thus reducing extrusion of debris and irrigants through the apical foramen. This is concerned with the amount of gutta-percha removed by Protaper Retreatment System, which was removed in big pieces around the instrument, whereas the manual ones enabled removal at smaller increments.<sup>28</sup> This performance

may be related to the reduction of contact area between ProTaper retreatment instruments and dentinal walls, increasing their efficiency compared to traditional manual instruments and, thus, corroborating our case report.

Another relevant aspect to be considered is the amount of debris extruded during endodontic reintervention, which represents a crucial factor for the prognosis of the clinical case. The amount of apically extruded debris during removal of filling material using Protaper rotary retreatment instruments, as well as D-RaCe, R-Endo and Hedstroen manual instruments, was evaluated. The group of manual instruments extruded significantly more debris than the rotary systems. However, there was no significant differences between Protaper, D-RaCe and R-Endo instruments;<sup>29</sup> thus, confirming the better performance of these systems, which supports and justifies their indication for the above-described clinical case.

With regard to the antisepsis of root canals in the removal of filling material using either Protaper retreatment rotary or reciprocating instruments (e.g., Reciproc and WaveOne), no significant differences were found in the reduction of microbial load, including by-products and endotoxins, which are factors of crucial importance regarding the maintenance of the aseptic chain.<sup>30</sup> The instruments used in the present study can be indicated for endodontic treatment planning.

## Conclusion

The use of rotary nickel-titanium systems for endodontic reintervention is a scientifically-supported reality in terms of clinical use, mainly because of the decreased apical extrusion of debris, in addition to reducing chair time compared to manual instruments. All these factors contribute to an adequate treatment planning and a more predictable prognosis.

The patient is currently being clinically and radiographically followed up. It is possible to observe that there was bone re-establishment and repair of the periapical region, including masticatory and esthetic functions of the tooth, thus characterizing the success of the proposed therapy.

## References

- Love RM. Regional variation in root dentinal tubule infection by *Streptococcus gordonii*. *J Endod*. 1996 Jun;22(6):290-3.
- Love RM, Jenkinson HF. Invasion of dentinal tubules by oral bacteria. *Crit Rev Oral Biol Med*. 2002;13(2):171-83.
- Vieira AR, Siqueira JF Jr, Ricucci D, Lopes WS. Dentinal tubule infection as the cause of recurrent disease and late endodontic treatment failure: a case report. *J Endod*. 2012 Feb;38(2):250-4.
- Vera J, Siqueira JF Jr, Ricucci D, Loghin S, Fernández N, Flores B, et al. One- versus two-visit endodontic treatment of teeth with apical periodontitis: a histobacteriologic study. *J Endod*. 2012 Aug;38(8):1040-52.
- Nair PN. Pathogenesis of apical periodontitis and the causes of endodontic failures. *Crit Rev Oral Biol Med*. 2004 Nov 1;15(6):348-81.
- Siqueira JF Jr, Rôças IN. Clinical implications and microbiology of bacterial persistence after treatment procedures. *J Endod*. 2008 Nov;34(11):1291-301.e3.
- Yesilsoy C, Gordon W, Porras O, Hoch B. Observation of depth and incidence of the mesial groove between the mesiobuccal and mesiolingual orifices in mandibular molars. *J Endod*. 2002 Jul;28(7):507-9.
- Mayer BE, Peters OA, Barbakow F. Effects of rotary instruments and ultrasonic irrigation on debris and smear layer scores: a scanning electron microscopic study. *Int Endod J*. 2002 Jul;35(7):582-9.
- Schirmeister JF, Wrbas KT, Meyer KM, Altenburger MJ, Hellwig E. Efficacy of different rotary instruments for gutta-percha removal in root canal retreatment. *J Endod*. 2006 May;32(5):469-72.
- Pirani C, Pelliccioni GA, Marchionni S, Montebugnoli L, Piana G, Prati C. Effectiveness of three different retreatment techniques in canals filled with compacted gutta-percha or Thermafil: a scanning electron microscope study. *J Endod*. 2009 Oct;35(10):1433-40.
- Takahashi CM, Cunha RS, Martin AS, Fontana CE, Silveira CF, Bueno CES. In vitro evaluation of the effectiveness of ProTaper universal rotary retreatment system for gutta-percha removal with or without a solvent. *J Endod*. 2009 Nov;35(11):1580-3.
- Venturi M. Evaluation of canal filling after using two warm vertical gutta-percha compaction techniques in vivo: a preliminary study. *Int Endod J*. 2006 Jul;39(7):538-46.
- Kokkas AB, Boutsoukias ACh, Vassiliadis LP, Stavrianos CK. The influence of the smear layer on dentinal tubule penetration depth by three different root canal sealers: an in vitro study. *J Endod*. 2004 Feb;30(2):100-2.
- Orstavik D. Materials used for root canal obturation: technical, biological and clinical testing. *Endod Top*. 2005;12(1):25-38.
- De Deus QD. Obtenção do canal radicular. In: *Endodontia*. 5a ed. Rio de Janeiro: Medsi; 1992. cap. 13, p. 445-535.
- Mollo A, Botti G, Principi Goldoni N, Randellini E, Paragliola R, Chazine M, et al. Efficacy of two Ni-Ti systems and hand files for removing gutta-percha from root canals. *Int Endod J*. 2012;45(1):1-6.
- Siqueira JF Jr, Araújo MC, Garcia PF, Fraga RC, Dantas CJ. Histological evaluation of the effectiveness of five instrumentation techniques for cleaning the apical third of root canals. *J Endod*. 1997;23(8):499-502.
- Nair PN, Sjögren U, Krey G, Kahnberg KE, Sundqvist G. Intraradicular bacteria and fungi in root-filled, asymptomatic human teeth with therapy-resistant periapical lesions: a long-term light and electron microscopic follow-up study. *J Endod*. 1990 Dec;16(12):580-8.
- Torabinejad M, Ung B, Kettering JD. In vitro bacterial penetration of coronally unsealed endodontically treated teeth. *J Endod*. 1990;16(12):566-9.
- Siqueira JF Jr, Rôças IN, Lopes HP, de Uzeda M. Coronal leakage of two root canal sealers containing calcium hydroxide after exposure to human saliva. *J Endod*. 1999 Jan;25(1):14-6.
- Molander A, Reit C, Dahlén G, Kvist T. Microbiological status of root-filled teeth with apical periodontitis. *Int Endod J*. 1998 Jan;31(1):1-7.
- Sundqvist G, Figdor D, Persson S, Sjögren U. Microbiologic analysis of teeth with failed endodontic treatment and the outcome of conservative re-treatment. *Oral Surg Oral Med Oral Pathol Oral Radiol Endod*. 1998 Jan;85(1):86-93.
- Oliveira DP, Barbizam JV, Trope M, Teixeira FB. Comparison between gutta-percha and resilon removal two different techniques in endodontic retreatment. *J Endod*. 2006 Apr;32(4):362-4.
- Tasdemir T, Yildirim T, Celik D. Comparative study of removal of current endodontic fillings. *J Endod*. 2008 Mar;34(3):326-9.
- Gu LS, Ling JQ, Wei X, Huang XY. Efficacy of ProTaper Universal rotary retreatment system for gutta-percha removal from root canals. *Int Endod J*. 2008 Apr;41(4):288-95.
- Somma F, Cammarota G, Plotino G, Grande NM, Pameijer CH. The effectiveness of manual and mechanical instrumentation for the retreatment of three different root canal filling materials. *J Endod*. 2008 Apr;34(4):466-9.
- Chandrasekar, Ebenezer AV, Kumar M, Sivakumar A. A comparative evaluation of gutta percha removal and of apical debris by rotary and hand files. *J Clin Diagn Res*. 2014 Nov;8(11):ZC110-4.
- Huang X, Ling J, Wei X, Gu L. Quantitative evaluation of debris extruded apically by using ProTaper Universal Tulsa rotary system in endodontic retreatment. *J Endod*. 2007 Sept;33(9):1102-5.
- Topçuoğlu HS, Aktı A, Tuncay Ö, Dinçer AN, Düzgün S, Topçuoğlu G. Evaluation of debris extruded apically during the removal of root canal filling material using ProTaper, D-RaCe, and R-Endo rotary nickel-titanium retreatment instruments and hand files. *J Endod*. 2014 Dec;40(12):2066-9.
- Martinho FC, Freitas LF, Nascimento GG, Fernandes AM, Leite FR, Gomes AP, et al. Endodontic retreatment: clinical comparison of reciprocating systems versus rotary system in disinfecting root canals. *Clin Oral Investig*. 2015 Jul;19(6):1411-7.