

Alveolodental ankylosis and subsequent replacement resorption: Can osseointegrated implants be placed in the same location?

Abstract: *Teeth with alveolodental ankylosis naturally evolve to replacement resorption. Provided that they remain free of microbial contamination, these teeth should be considered in the bone context as one more structure that should undergo continuous remodeling. Continuous remodeling is one of the most remarkable characteristics of bone biology, given that it is responsible for keeping blood calcium, as well as other minerals essential to life, levels stable. Another consequence of alveolodental ankylosis is the gradual infraocclusion of the affected tooth. Provided that free of microbial contamination, the areas of bone with root or root fragments undergoing replacement resorption can remain in the sites where surgical sockets are prepared to receive osseointegrated implants which shall not hinder the process of peri-implant bone repair also known as osseointegration. In the event of being contaminated by bacteria and their byproducts, the root structure should be eliminated. The remaining site should be further assessed to indicate potential corrections of volume and shape.* **Keywords:** Replacement resorption. Alveolodental ankylosis. Osseointegrated implants. Tooth resorption.

Alberto CONSOLARO

Full professor, School of Dentistry —USP/ Bauru and professor of the postgraduate program at the School of Dentistry — USP/ Ribeirão Preto.

How to cite this article: Consolaro A. Alveolodental ankylosis and subsequent replacement resorption: Can osseointegrated implants be placed in the same location? *Dental Press Implantol.* 2014 July-Sept;8(3):10-4. doi: <http://dx.doi.org/10.14436/2237-650X.8.3.010-014.exp>

Submitted: July 4, 2014 - **Revised and accepted:** July 18, 2014

Contact address: consolaro@uol.com.br

» The author informs he has no associative, commercial, intellectual property or financial interests representing a conflict of interest in products and companies described in this article.

INTRODUCTION

Tooth resorption has become the major cause of tooth loss. Nevertheless, there still exists considerable confusion over its differential diagnosis. Tooth resorption is grouped according to seven different criteria,¹ based on which each one of its different types receives an appropriate and distinct name.

Based on their mechanism of occurrence, resorptions are divided into two types:

- 1) **Inflammatory resorption:** It occurs when inflamed periodontal space and periodontal ligament are kept during the process. Both of them represent a source of mediators that allow the cells to trigger resorption of mineralized root tissues. It is caused by periapical periodontitis, orthodontic movement, trauma, etc. From the point of view of the cell, the cause of resorption led to the death of cementoblasts. However, the periodontal ligament preserved the epithelial rests of Malassez which represent the structure responsible for keeping the periodontal space uniform and stable, thereby preventing alveolodental ankylosis.
- 2) **Replacement resorption:** It occurs whenever alveolodental ankylosis is established as a result of trauma in erupted teeth (Fig 1) or significant atrophy of the periodontal ligament in unerupted teeth. Whenever a tooth suffers from alveolodental ankylosis, it is considered a bone structure that will subsequently be subjected to ongoing renewal. As a result, the tooth will be completely remodeled and replaced by bone.

ALVEOLODENTAL ANKYLOSIS AND ITS CONSEQUENCES

The periodontal ligament is on average 0.25 mm thick, with values ranging from 0.2 to 0.4 mm. The epithelial rests of Malassez are responsible for preserving the periodontal space. They are three-dimensionally arranged in a web-like shape throughout the entire periodontal ligament. As it occurs with any epithelium, these structures constantly release a mediator known as EGF (epidermal growth factor) which acts over the receptors of their own cells with a view to keeping proper proliferation as well as preserving their structures.

As a result, the periodontal ligament is permeated with this mediator that, in bone cells receptors, triggers bone resorption. By means of this mechanism, living organisms keep the periodontal space and the alveolar bone uniform, stable and far from the tooth root, thereby preventing ankylosis. Alveolodental ankylosis only occurs when, in the periodontal ligament, the epithelial rests of Malassez die, most of times as a result of tooth trauma.

The major consequence of alveolodental ankylosis is that it includes the affected tooth in the process of bone turnover in such a way that its root is gradually replaced by normal bone tissue (Fig 1). Clinically, the tooth with alveolodental ankylosis tend to slowly and progressively undergo infraocclusion. Negative response to vertical percussion and loss of tooth mobility are subtle and hardly ever detectable signs.

REPLACEMENT TOOTH RESORPTION AND ITS CONSEQUENCES

Whenever bone adheres to the mineralized tooth structure, the ongoing process of resorption, typical of bone remodeling,

will naturally include the tooth which, in turn, will be gradually replaced by bone that is completely normal from a biological and physical standpoint.

For these reasons, it is reasonable to assert that it is natural that alveolodental ankylosis will evolve to replacement resorption, with no exceptions. Dental tissue is denser in comparison to trabecular bone and the volume of each tooth root considerably varies. For this reason, it is impossible to foresee the amount of time within which all components of tooth structure will be replaced.

With regard to maintenance of the tooth affected by replacement resorption and the possibility of restoring normality, the prognosis is unsatisfactory: There will unavoidably be tooth loss.

TOOTH LOSS AS A RESULT OF REPLACEMENT RESORPTION

All teeth affected by replacement resorption will be lost. Should that be the case, the major concern is to know when and in which clinical and biological circumstances it will be.

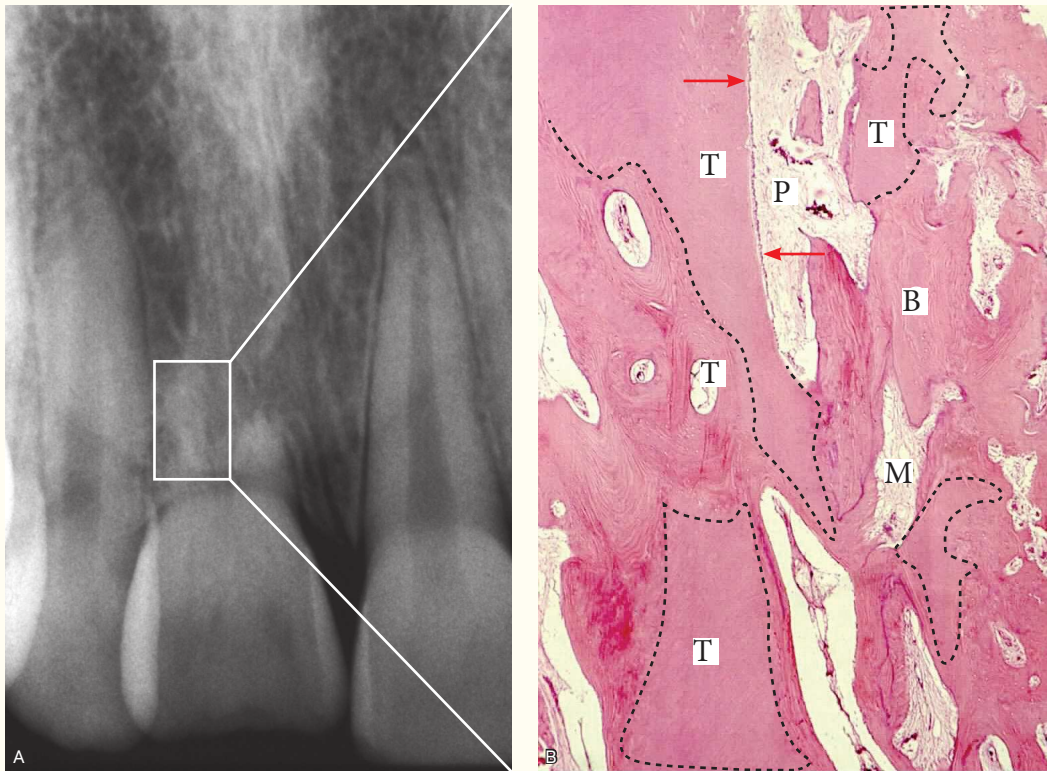


Figure 1. In case of replacement resorption, tooth fragments (T) remain at the site for long periods, as they are absorbed in the process of bone remodeling. Some tooth fragments (T) present a layer of odontoblasts (arrow) and pulp (P). In areas where the tooth structure was already replaced, bone (B), with its trabeculae and medullary spaces, is normally structured (M = medullary spaces) (H.E.; B = 40 X).

1) One of the circumstances is when the course of replacement resorption naturally flows without intervention. After a few months or years, the crown will have steadily adhered to the bone on its cervical surface, thereby resulting in a true crown-bone interface. At any moment, if subjected to significant physical demand, the crown might unpredictably detach.

One major inconvenient of the natural evolution of replacement resorption is the possibility of having bacteria coming from dental plaque and affecting surrounding gingival tissues, thereby triggering inflammation and harming gingival tissues at the cervical level. Additionally, these bacteria could also lead to inflammation and contamination of the crown-bone interface and, as a result, also harm and make bone unfeasible for future procedures.

2) Should the tooth had been endodontically treated, the gutta-percha cones remain at site, with or without filling cement depending on its composition. In these cases, should the crown-bone interface break, the endodontic material can be easily removed, given that osseointegration is nonexistent and its surface is covered by a thin pellicle of soft tissue that accounts for foreign body granuloma.

3) Another major circumstance associated with tooth loss caused by replacement resorption is the contamination of the remaining structure by bacteria and/or their by-products, such as lipopolysaccharides. Contamination might have happened during or soon after trauma, or by communication established with gingival tissues, secondary fracture or severe periodontal disease.

In general, should the remaining structure be contaminated, the process of tooth loss tends to occur at a disordered and faster pace in association with a fistula.

HOW TO DEAL WITH A TOOTH AFFECTED BY REPLACEMENT RESORPTION

- 1st) Plan tooth extraction or clinically assisted natural tooth loss by inducing occlusion or mild traumatic occlusion so as to speed it up. The latter allows bone volume, including bone at the gingival level, to be preserved (Fig 1).
- 2nd) Plan orthodontic space closure.
- 3rd) Plan osseointegrated implant placement with or without previous extraction. It is not advisable to include a tooth affected by replacement resorption in rehabilitation treatment, since it will be inevitably lost despite considerable amount of root remaining: Tooth loss will only be a matter of time. Should the affected teeth be subjected to force within the context of rehabilitation, prosthetic treatment, replacement resorption tends to speed up.
- 4th) Should teeth affected by replacement resorption be contaminated, the following must be considered in treatment planning: a) Eliminate fragments of contaminated mineralized tissue; b) Perform surgical curettage; c) Subject the area to antibiotic therapy; d) Perform postoperative follow-up to ensure that remaining tissues were restored to normality. After carrying out the aforementioned procedures, it is advisable to conduct assessment and planning which shall include bone and

gingival tissue grafting as well as other procedures necessary to re-establish the anatomical shape of the site and, as a result, favor osseointegrated implant placement.

IS THE BONE THAT REPLACES THE ROOT NORMAL? DO ROOT FRAGMENTS INVOLVED IN REPLACEMENT RESORPTION HINDER OSSEOINTEGRATION?

Once alveolodental ankylosis is established, the bone remodels the dental space and tissue it adhered in its structure (Fig 1). Bone tissue, dentin and cementum end up forming a web of mineralized tissue which bone cells cannot differentiate. In other words, bone cells see mineralized dental tissue as tissue subjected to natural resorption, as if they were normal bone (Fig 1).

Provided that the site is not contaminated by bacteria, the surgical socket might be prepared for osseointegrated implant placement. Should that be the case, peri-implant repair will occur within normal conditions. The advantage of not removing all tooth fragments lies in the preservation of cervical tissue and bone volume, which favors final implant outcomes in terms of function and esthetics. The interface between osseointegrated implant and fragments of dental tissue will not hinder osseointegration, unless tooth fragments are contaminated.

A tooth subjected to dental trauma, provided that properly managed, may undergo endodontic treatment, in general, 15 days later, without microbial contamination of the root. Many teeth affected by replacement resorption present with pulp vitality (Fig 1). The clearest sign of contamination of the remaining root structure is the presence of fistula or drainage through the gingival sulcus.

FINAL CONSIDERATIONS

Teeth with alveolodental ankylosis naturally evolve to replacement resorption. Provided that they remain free of microbial contamination, these teeth should be considered, in the bone context, as another structure undergoing continuous remodeling (Fig 1). Continuous remodeling is one of the most remarkable characteristics of bone biology, given that it is responsible for keeping blood calcium, as well as other minerals essential to life, levels stable.

Provided that free of microbial contamination, the areas of bone with root or root fragments undergoing replacement resorption can remain in the sites where surgical sockets are prepared to receive osseointegrated implants which shall not hinder the process of peri-implant bone repair also known as osseointegration.

REFERENCES:

1. Consolaro A. Reabsorções dentárias nas especialidades clínicas. 3a ed. Maringá: Dental Press; 2012.