
Platelet-rich fibrin membrane in immediate dental implant loading

Carlos Fernando de Almeida Barros **MOURÃO**¹, Natália Belmock Mascarenhas Freitas **MOURÃO**²

Abstract / Introduction: one of the main concerns shared by dental surgeons after implant or bone graft biomaterial placement is the exposure to the oral cavity, which might lead to bone graft failure due to surgical site infection. The alternatives used to protect these types of material are connective tissue and alloplastic membranes. **Objective:** the aim of this study is to present an alternative to protect these types of material after placement, using platelet-rich fibrin clot (PRF) as a protection barrier. **Methods:** patient was subject to extraction with immediate implant placement, associated with bone graft biomaterial between the implant and the alveolar wall, followed by fibrin membrane clot fitting over the prosthetic abutment for further adaptation of a provisional prosthesis. **Results:** during healing of the surgical wound, the patient did not present any adverse reactions. **Conclusion:** it is possible to use PRF as a protection barrier for bone graft biomaterial used during placement of immediate-loaded dental implants.

Keywords: Immediate dental implant loading. Fibrin. Biocompatible material.

104

¹Professor of Oral and Maxillofacial Surgery, Pharmacology and Mouth Anatomy, Faculdades São José, Rio de Janeiro, Rio de Janeiro, Brazil.

²Masters student in Administration and Pharmaceutical Services Management, Universidade Federal Fluminense, Niterói, Rio de Janeiro, Brazil.

How to cite this article: Mourão CFAB, Mourão NBMF. Platelet-rich fibrin membrane in immediate dental implant loading. Dental Press Implantol. 2015 Jan-Mar;9(1):104-9. doi: <http://dx.doi.org/10.14436/2237-650X.9.1.104-109.oar>

Submitted: 5/12/2014 - **Revised and accepted:** 6/03/2015

Contact address: Carlos Fernando de Almeida Barros Mourão
Avenida de Santa Cruz, 580 - Realengo - Rio de Janeiro/RJ - Brazil - CEP: 21710-232
E-mail: mouraoufrj@yahoo.com.br

» The authors report no commercial, proprietary or financial interest in the products or companies described in this article.

» Patients displayed in this article previously approved the use of their facial and intraoral photographs.

INTRODUCTION

Bone graft exposure to the oral cavity is always of great concern to dental surgeons due to potential loss of implanted biomaterial or the possibility of surgical site infection. Therefore, some techniques were developed with a view to avoiding these complications;¹⁻⁴ for instance, the use of autogenous material, such as connective tissue;^{1,2} or alloplastic material, such as polytetrafluoroethylene (PTFE) membrane.^{3,4}

Advances in Bioengineering and the development of new guided bone regeneration techniques allowed some regenerative procedures to be refined. Among these, we highlight the inclusion of fibrin clot (PRF) or platelet-rich fibrin.⁵

Created in France by the French doctor Joseph Choukroun, PRF is a second-generation platelet concentrate, obtained from blood prepared by centrifugation, which has been widely used to accelerate healing of soft and hard tissues.⁵

Blood is removed and immediately centrifuged. Blood activation occurs during centrifugation, which allows a dense fibrin and platelet clot to form in the middle of the tube, between the basis of red blood cells, at the bottom, and acellular plasma, at the top of the tube.^{6,7} The clot may be used, directly or after light compression, to remove excess blood plasma, acting as a hard membrane.

The present study describes the use of this autogenous membrane as a form

of protection and maintenance of biomaterial implanted after immediate implant loading.

CASE REPORT

A 20-year-old healthy patient, with no history of diseases or previous allergies, arrived at the clinic with chief complain of tooth fracture. Clinical examination revealed severe crown fracture of a left maxillary first premolar (tooth #24) (Fig 1).

After tomographic examination, three treatment options were presented. The patient opted for rehabilitation with dental implant performed by means of the immediate loading technique. Before the surgical procedure, the patient had approximately 12 ml of blood collected for PRF membrane production. A horizontal centrifuge, at 2400 rpm, was used during ten minutes.

For the surgical procedure, a Morse Taper (Drive Neodent Implant) implant, 3.5 mm in diameter and 13-mm high, was used. After tooth extraction, the implant was placed into the socket, and drilling was carried out with a lance drill (Neodent), with the aid of a 20:1 reduction contra-angle handpiece (400 rpm). Subsequently, bone expansion was performed with lip bumpers (Neodent), progressively up to 2.8 mm.

Implant placement began with the contra-angle handpiece and finished with a torque gauge (Neodent), with good primary stability (50 N).

Hydroxyapatite (Alobone Poros, Osseocon) was placed into the buccal and lingual gaps formed between the bone wall and the implant. Subsequently, the prosthetic abutment, 3.3 mm in diameter, 3.5 mm of neck height and 6.0-mm high, was placed (Fig 2).

After abutment placement, the PRF membrane was produced. The fibrin clot was removed from the collection tube and light compression was applied with the aid of a sterile gauze. Once the membrane was ready, a small incision was made halfway through it, and the membrane was then transfixed (Fig 3). Perforation allowed the membrane to be placed over the prosthetic abutment, leaving it exposed and covering the biomaterial previously placed

into the tooth socket (Fig 4). After the provisional prosthesis had been manufactured and cemented with calcium hydroxide-based cement, synthesis was carried out in the papillae region with a 6-0 nylon wire (Fig 5).

The patient was advised to clean the surgical site with 0.2% chlorhexidine gel and take 500-mg naproxen sodium every eight hours for five days, and 750-mg paracetamol every six hours for three days. He was monitored every three days during the first week and on a weekly basis until the end of the first month (Figs 6,7). By the end of the sixth month, the patient presented with excellent gingival conditions, without the need for etching to manufacture a definitive prosthesis (Fig 8).

106

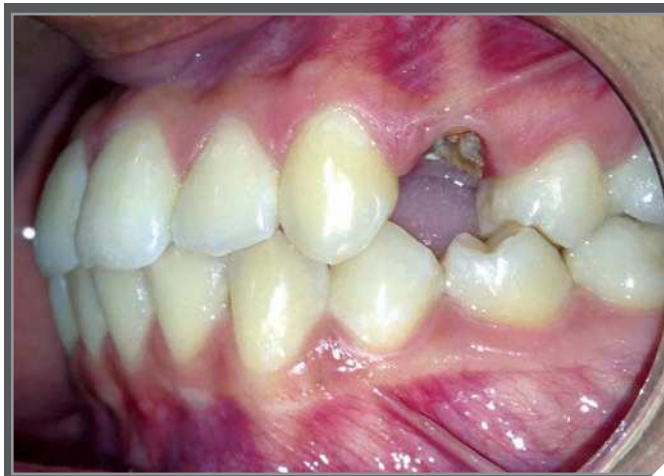

Figure 1. Tooth #24 with crown fracture.

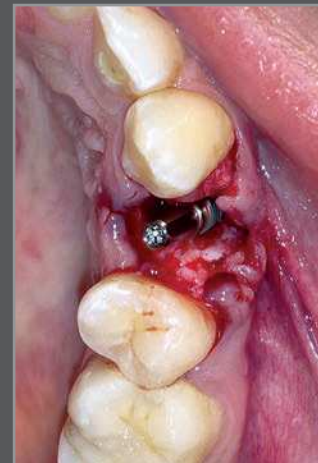

Figure 2. Dental implant fitting with the prosthetic abutment placed into the alveolar bone.

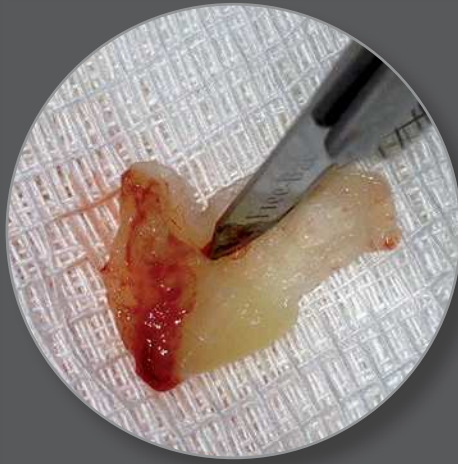


Figure 3. Incision carried out in the PRF membrane.

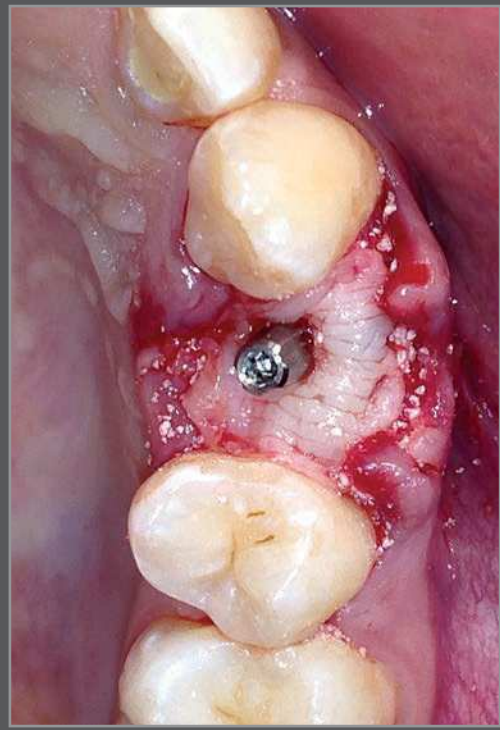


Figure 4. PRF membrane fitting over the prosthetic abutment, protecting the biomaterial and the dental implant.

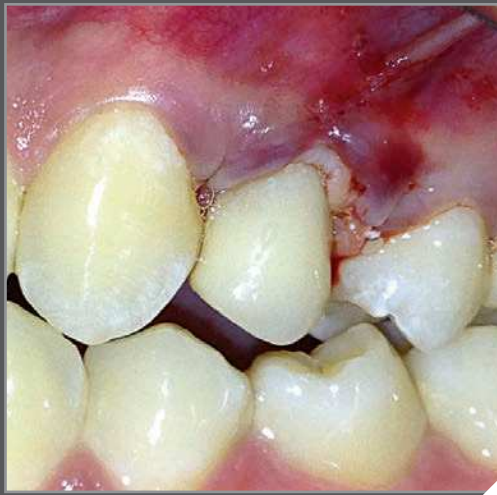

Figure 5. Finishing the surgical procedure with provisional implant fitting.

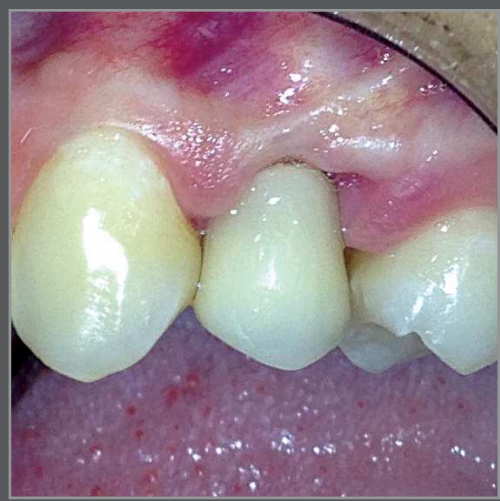

Figure 6. Follow-up 15 days after the surgical procedure.

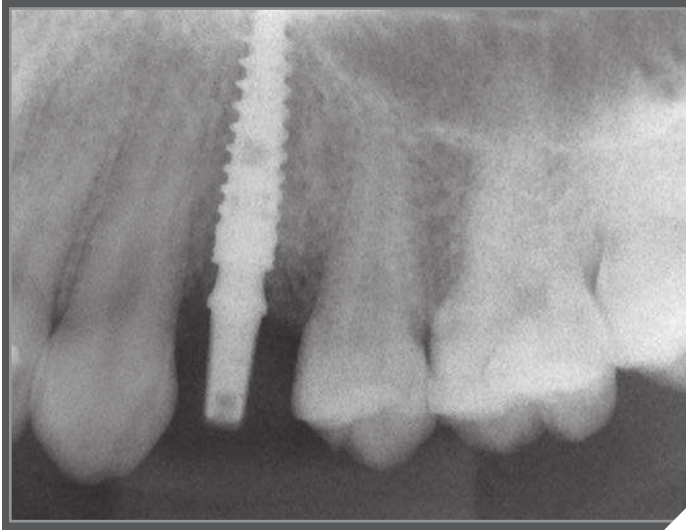


Figure 7. Periapical radiograph 30 days after surgery.

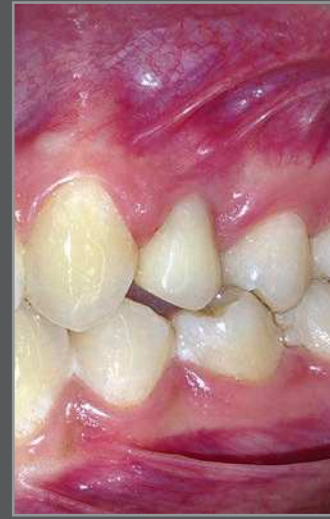

Figure 8. Mucosa conditions after six months.

DISCUSSION

The use of material to avoid bone graft or dental implant exposure to the oral cavity is a reality in daily clinical practice. Techniques employing connective tissue¹ or keratinized tissue² are safe because they present low infection rates and zero potential for rejection. However, these techniques require considerable professional expertise and imply increased surgical morbidity, as they need a donor site.

Alloplastic membranes are easily handled and placed by the surgeon; in addition, they avoid increased morbidity risks. Nevertheless, this type of membrane not only increases infection risks, when compared to autogenous material, but also boost operative costs involved in membrane production.⁴ The PRF membrane is a low-priced and easy-to-obtain autogenous material.

It has already been demonstrated that the PRF membrane slowly releases significantly amounts of growth factors (TGF β 1, PDGF-AB, VEGF) and thrombospondin-1 (TSP-1) during, at least, seven days.⁸ Moreover, it has already been used to replace connective tissue in periodontal surgery.⁹

CONCLUSION

PRF membrane is an autogenous material with properties that benefit tissue regeneration, which renders its manipulation around prosthetic abutments easier during fitting. It may be used as a protective barrier for alloplastic material placed in the oral cavity, and as an alternative to periosteal incision when the dental surgeon opts for synthesis.

REFERENCES:

1. Nemcovsky CE, Artzi Z, Moses O. Rotated split palatal flap for soft tissue primary coverage over extraction sites with immediate implant placement. Description of the surgical procedure and clinical results. *J Periodontol*. 1999;70(8):926-34.
2. Nemcovsky CE, Artzi Z, Moses O. Rotated palatal flap in immediate implant procedures. Clinical evaluation of 26 consecutive cases. *Clin Oral Implants Res*. 2000;11(1):83-90.
3. Yun JH, Jun CM, Oh NS. Secondary closure of an extraction socket using the double-membrane guided bone regeneration technique with immediate implant placement. *J Periodontal Implant Sci*. 2011;41(5):253-8.
4. Carbonell JM, Martín IS, Santos A, Pujol A, Sanz-Moliner JD, Nart J. High-density polytetrafluoroethylene membranes in guided bone and tissue regeneration procedures: a literature review. *Int J Oral Maxillofac Surg*. 2014;43(1):75-84.
5. Dohan DM, Choukroun J, Diss A, Dohan SL, Dohan AJ, Mouhyi J, Gogly B. Platelet-rich fibrin (PRF): a second-generation platelet concentrate. Part I: technological concepts and evolution. *Oral Surg Oral Med Oral Pathol Oral Radiol Endod*. 2006;101(3):e37-44.
6. Dohan Ehrenfest DM, Bielecki T, Jimbo R, Barbé G, Del Corso M, Inchingolo F, Sammartino G. Do the fibrin architecture and leukocyte content influence the growth factor release of platelet concentrates? An evidence-based answer comparing a pure platelet-rich plasma (P-PRP) gel and a leukocyte- and platelet-rich fibrin (L-PRF). *Curr Pharm Biotechnol*. 2012;13(7):1145-52.
7. Dohan Ehrenfest DM, Del Corso M, Diss A, Mouhyi J, Charrier JB. Three-Dimensional Architecture and Cell Composition of a Choukroun's Platelet-Rich Fibrin Clot and Membrane. *Curr Pharm Biotechnol*. 2012;13(7):546-55.
8. Dohan Ehrenfest DM, Peppo GM, Doglioli P, Sammartino G. Slow release of growth factors and thrombospondin-1 in Choukroun's platelet-rich fibrin (PRF): a gold standard to achieve for all surgical platelet concentrates technologies. *Growth Factors*. 2009;27(1):63-9.
9. Jankovic S, Aleksic Z, Klokkevold P, Lekovic V, Dimitrijevic B, Kenney EB, Camargo P. Use of platelet-rich fibrin membrane following treatment of gingival recession: a randomized clinical trial. *Int J Periodontics Restorative Dent*. 2012;32(2):e41-50.