

First mandibular premolar with three canals: case report

Julia Gabiroboertz **CARDOSO**¹
 Camila Leão de **AZEVEDO**¹
 Arthur Pimentel **BARROSO**²
 Jefferson José de Carvalho **MARION**³
 Thaís Mageste **DUQUE**⁴
 Maíra do **PRADO**⁵

DOI: <http://dx.doi.org/10.14436/2358-2545.7.1.014-019.oar>

ABSTRACT

Objective: The aim of this case report was to describe the endodontic treatment of a mandibular first premolar with three canals. **Case report:** A 54-year-old male patient sought Federal University of Rio de Janeiro (UFRJ) emergency care with painful tooth #34. Clinical/radiographic examination revealed severe caries. Pulp sensibility tested positive and exacerbating, with no periapical symptoms at palpation and percussion. Therefore, the patient was diagnosed with irreversible pulpitis. He was subjected to anesthesia, kept under rubber dam isolation and subjected to root canal access. Mechanical preparation was carried out by the crown-down technique, with working length set at

1mm from the root apex in all three canals. 2.5% sodium hypochlorite was used as irrigating solution, whereas 17% EDTA was used to remove smear layer. Root canal filling was carried out by Tagger's hybrid technique with Endofill sealer and gutta-percha cones. Final radiograph revealed the presence of three canals, one lingual and two buccal ones, all of which were at the apical third starting point. A furcation connecting the buccal canals (intercanal) was also found. **Final considerations:** Knowing and mastering root canal anatomical traits are key factors to achieve success in endodontic treatment.

Keywords: Premolar. Root canal treatment. Root canal filling.

How to cite: Cardoso JG, Azevedo CL, Barroso AP, Marion JJC, Duque TM, Prado M. First mandibular premolar with three canals: case report. *Dental Press Endod.* 2017 Jan-Apr;7(1):14-9.
 DOI: <http://dx.doi.org/10.14436/2358-2545.7.1.014-019.oar>

¹Private practice (Rio de Janeiro/RJ, Brazil).

²Private practice (Campo Grande/MS, Brazil).

³Universidade Federal do Mato Grosso do Sul, Faculdade de Odontologia, Departamento de Endodontia (Campo Grande/MS, Brazil).

⁴Universidade Federal de Santa Catarina, Departamento de Endodontia (Florianópolis/SC, Brazil)

⁵Universidade Veiga de Almeida, Faculdade de Odontologia (Rio de Janeiro/RJ, Brazil).

» The authors report no commercial, proprietary or financial interest in the products or companies described in this article.

» Patients displayed in this article previously approved the use of their facial and intraoral photographs.

Submitted: May 05, 2016. Revised and accepted: November 23, 2016.

Contact address: Jefferson José de Carvalho Marion
 Rua Cora Coralina 189, Chácara Cachoeira
 CEP: 79.040-510 / Campo Grande/MS - Brasil
 E-mail: jefferson@jmarion.com.br

Introduction

Complete cleaning and shaping combined with hermetic filling of the root canal system is the key to achieve success in correct endodontic treatment.¹ Knowing internal root canal system anatomical traits is of paramount importance, given that anatomical variations are common findings during endodontic treatment.^{2,3,4}

In 1925, Hess⁵ assessed the internal anatomical traits of different teeth, among which were mandibular premolars. The author found out that 2.5% of mandibular premolars he had assessed presented with more than one canal. In the following year, Okumura⁶ assessed 140 mandibular premolars and found out that 15% of them presented with two canals. Other traditional study⁷ employing the clearing technique revealed 2.1% of 102 mandibular premolars assessed by the author presented with three root canals. Pineda and Kuttler⁸ conducted a radiographic analysis and found out that 12% of assessed teeth presented with two or more root canals. Dotto et al⁹ reported a clinical case of mandibular premolar with three root canals.

Due to great anatomical variation found among mandibular premolars, those teeth might pose a challenge to a successful endodontic treatment.³ In this sense, Vertucci and Gegauff¹⁰ found out that mandibular first premolars presented with one canal in the root apex of 74% of assessed teeth, two canals in the apex of 25.4% of teeth, and three canals in 0.5% of assessed teeth. Furthermore, as regards root canal system analysis, Vertucci¹¹ concluded that out of 400 mandibular first premolars assessed, 44.3% presented with lateral canals, most of which were located in the apical portion. The study also revealed that 32.1% of teeth had transverse anastomosis most commonly found in root canals middle third.

Computer tomography, a technique that provides images in different plans according to different thicknesses, is an important tool used to study and make anatomical structures visible. It is considered one of the most accurate techniques for root canal location and identification.¹² Recent studies employing the technique have shown considerable anatomical variations in mandibular premolars not only regarding the number of roots and canals in different populations, but also root in terms of canal shape and the presence of C-shaped canals.¹³⁻¹⁶

Thus, the present study reports a clinical case of a single-rooted mandibular premolar with three canals, in addition to the approach employed to achieve a hermetic sealing of the root canal system.

Case report

A 54-year-old male patient sought emergency care at Federal University of Rio de Janeiro (UFRJ), School of Dentistry, with major complaint of painful symptoms in his left mandibular first premolar (tooth #34).

During the first interview, the patient reported having anemia and hepatitis A, as well as having been subjected to blood transfusion due to an accident he had suffered 20 years before. He did not report using any type of prosthesis nor having hemorrhage after surgery, and, as of this time, he has presented no adverse reactions to any medication or anesthetic drug. As regards the use of medication, the patient reported taking painkiller to relieve painful symptoms caused by the affected tooth.

Clinical examination revealed absence of some teeth, in addition to severe caries in tooth #34. Since the primary goal of emergency care is relieving patient's pain, care aimed at diagnosis and treatment of tooth #34. Radiographic clinical examination revealed severe caries affecting the pulp chamber. As regards root anatomical traits, radiographic examination revealed root canal light only at the cervical third (Fig 1).

Patient's pulp sensibility tested positive and exacerbating, with no periapical symptoms (negative palpation and percussion). Once irreversible pulpitis diagnosis was achieved, the patient was subjected to anesthesia with 2% lidocaine associated with

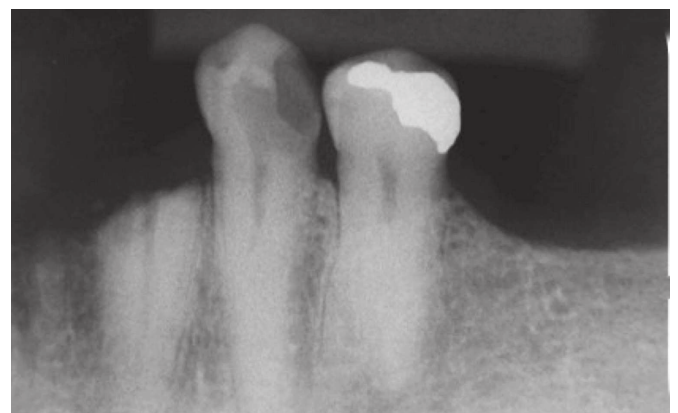


Figure 1. Initial radiograph. Tooth #34 evincing severe caries with root canal light visible only at the cervical third.

epinephrine 1:1000.000 (DFL, Rio de Janeiro, RJ, Brazil). Subsequently, he was kept under rubber dam isolation and subjected to caries removal, with endodontic access carried out with the aid of a 1014 diamond bur (KG Sorensen, Cotia, SP, Brazil) and CA4 steel bur (Dentsply, Petrópolis, RJ, Brazil).

Preparation was carried out by the crown-down technique. Tooth length was assessed with the aid of radiographic examination revealing it to be 23mm long. During the first visit, preparation was carried out in the middle-cervical third of root canals at 17mm. Kerr files #15 to #40 (Dentsply, Petrópolis, RJ, Brazil) were used up to that length. Irrigation with 2.5% sodium hypochlorite (Asfer, São Caetano do Sul, SP, Brazil) was carried out for every three files, in addition to patency with Kerr file #10 at 18mm. Subsequently, step back instrumentation was performed with an increasing sequence of Gates-Glidden drills (GG) from #1 to #4 (GG1 at 17mm, GG2 at 15mm, GG3 at 13mm, and GG4 at 11mm). Between GG1/2 and GG3/4, irrigation with sodium hypochlorite and patency with Kerr file #10 at 18mm were carried out. Once middle-cervical third preparation was finished, copious irrigation was performed with sodium hypochlorite, in addition to the use of camphorated para-mono-chlorophenol (Biodinâmica, Ibioporã, PR, Brazil) as intracanal dressing, and coltosol (Vigodent, Rio de Janeiro, RJ, Brazil) as temporary dressing.

In the following week, the patient was subjected to anesthesia and rubber dam isolation for removal of the temporary dressing. Additionally, working length was determined at the different root canals (Fig 2). During root canal assessment for odontometry, the clinician found out buccal canals were connected, ending in a single foramen. For this reason, odontometry was performed with the file inserted in one canal only. Working length was determined at 1mm from the radiographic apex (22mm in all three canals). Preparation was then carried out in the apical third by means of the apical stop technique combined with scaling. K-files #10 to #25 were used for

apical stop manufacturing. As for scaling, K-files #35 to #60 were used in ascending order up to the middle third (K-file #35 at 21mm, K-file #40 at 20mm, K-file #45 at 19mm, K-file #50 at 18mm, K-file #55 at 17mm, and K-file #60 at 16mm). Copious irrigation with sodium hypochlorite was carried out for every three files, in addition to patency with Kerr file #10 at 23mm.

17% EDTA was used during three minutes for smear layer removal, with replacements every minute. Saline solution was used as final irrigating solution. All cones used were decontaminated with sodium hypochlorite for one minute.

Subsequently, cone try-in (Fig 3) was carried out. Since buccal canals were located at the middle third starting point, one canal was chosen for anchorage of the main gutta-percha cone. In both canals (buccal and lingual), cone #25 was used as the main cone. Once cone try-in was finished, the canal was dried with the aid of sterile paper cones (Dentsply, Petrópolis, RJ, Brazil).

Endofill sealer (Dentsply, Petrópolis, RJ, Brazil) was used for filling carried out by Tagger's hybrid technique. The sealer was prepared following the manufacturer's instructions. Initially, the main cones were sealed. Subsequently, FF and FM cones (Dentsply, Petrópolis, RJ, Brazil) were associated with endodontic sealer and used as accessory cones for root canal filling. Gutta-percha was sectioned in the cervical region and thermocompacted with a McSpadden condenser #40 (Dentsply, Petrópolis, RJ, Brazil) 4mm from the working length. A radiograph was obtained to assess root canal filling quality. Lastly, pulp chamber cleaning was carried out with alcohol followed by root canal sealing with temporary sealer (coltosol).

Final radiograph (Fig 4) reveals the presence of three canals, one lingual and two buccal ones, all of which were at the apical third starting point. A furcation connecting the buccal canals, known as intercanal, was also found (Fig 4 arrow).

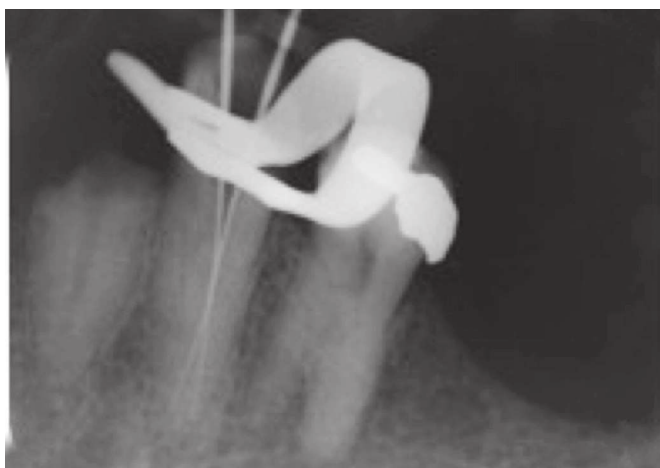

Figure 2. Radiographs used to determine the working length.

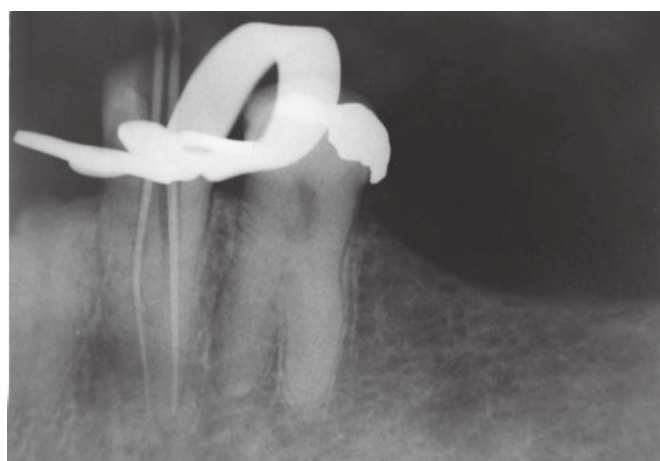
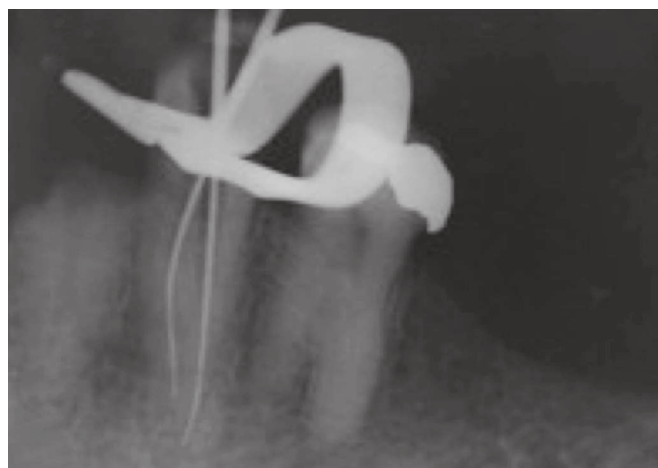


Figure 3. Main cones try-in radiograph.

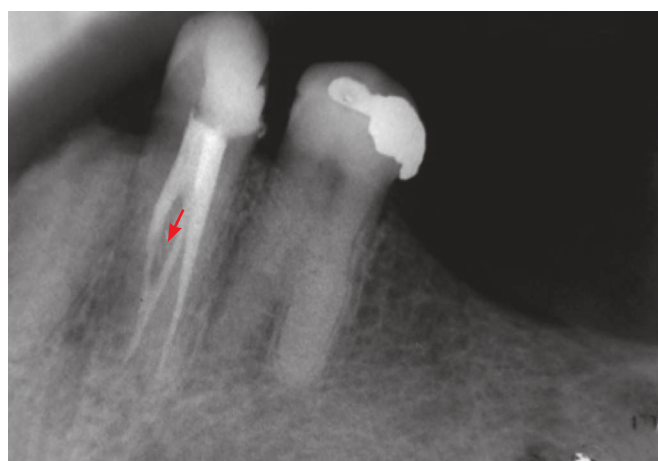


Figure 4. Final radiograph showing three canals, one lingual and two buccal ones, connected by an intercanal (arrow).

Discussion

Knowing root canal system anatomical traits, as well as potential variations, exerts direct influence on endodontic treatment prognosis. Should anatomical variation be identified at treatment onset, major changes might be carried out in treatment planning, thus increasing the chances of achieving satisfactory and safe outcomes.^{17,18} The possibility of finding more than one root canal in a mandibular premolar should always be taken into consideration.¹⁹

Variation on the number of roots and canals found in mandibular premolars is a major finding in the literature.¹³⁻¹⁶ Even though the presence of one single root and one canal (Vertucci Type I) is the most common for mandibular premolars, two and three canals might be found as well.⁵⁻⁹ Those canals might have only one, two or up to three foraminal openings; however, the latter is rather rare.¹⁰ Literature findings reveal the following: teeth with two canals in the pulp chamber, being connected at the middle/apical

third (Vertucci Type II); teeth with one single canal in the pulp chamber, bifurcating at the middle third and reconnecting at the apical third (Vertucci Type III); teeth with two canals at the entire root extension (Vertucci Type IV); and teeth with one single canal in the pulp chamber, bifurcating into two canals and two foramina (Vertucci Type V) at the root middle third; or three canals and three foramina (Vertucci Type VIII).⁵⁻¹⁰

In the present study, initial radiographic analysis was suggestive of the presence of more than one canal due to image interruption of the root canal in the middle third.²⁰ Confirmation was achieved during preparation, in which three canals were identified.

Different radiographic examinations revealed the presence of more than one canal and one groove at the middle and apical thirds. No radiographic examination revealed the presence of more than one root. The root was seen through a root bifurcation. Such bifurcation could be easily identified in the tooth adjacent to the treated tooth (second premolar). The literature shows that the presence of root grooves often results in the emergence of more than one canal in mandibular premolars, regardless of the existence of root bifurcation.²¹ Furthermore, single-rooted mandibular premolars might present with one single canal or up to three canals.^{13-16,22,23}

Treatment success is also related to adequate instrumentation, as well as root canal proper cleaning and shaping, thus allowing high-quality filling.²⁰ The crown-down technique starts with complete cleaning and shaping of the root canal as from the coronal third towards the apical third, with the latter being the final step. According to Cohen and Hargreaves,²⁵ the technique has advantages, such as eliminating root canal constriction in the coronal region; decreasing root canal curvature - which favors cleaning and shaping in the apical region; allowing effective irrigation throughout the canal; removing the main pulp portion as well as infectious microorganisms before reaching the apical third; and allowing lower probability of changes to the working length.

The limits of instrumentation and filling are set by most authors as 1mm from the root apex radiographically seen, as noted by Ricucci.²⁶ They might undergo changes of about 0.5mm according to pulp conditions. According to Holland et al,²⁷ repair is

very closely related to the apical limits of filling, with greater repair rates when filling remains 1mm from the root apex.

White et al²⁸ proved that the presence of smear layer in the root canal system after instrumentation hinders penetration of filling material into dentin tubules; thus rendering its complete removal for perfect material penetration necessary.²⁹ For proper removal of smear layer organic matter, sodium hypochlorite (NaOCl) remains as the gold standard of tissue dissolution. However, the substance does not affect smear layer inorganic matter, in which case NaOCl must be used in combination with ethylenediaminetetraacetic acid (EDTA), thus resulting in smear layer complete removal.³⁰⁻³²

In the present study, Tagger's hybrid technique was used for hermetic, tridimensional filling of the root canal system. In 1984, Tagger introduced a hybrid filling technique to Endodontics, combining traditional lateral condensation with a compactor used for gutta-percha thermoplastification. The technique is advantageous for avoiding displacement and extrusion of gutta-percha previously subjected to lateral condensation at the apical level, in comparison to Schilder's technique.²⁰ Camões et al³³ and Tavares et al³⁴ proved that Tagger's hybrid technique provides a homogeneous, compact filling matter (gutta-percha + filling sealer), thus reducing potential risks of overfilling.

The pulp space is complex, since root canals might furcate or connect, thus altering their shape. Additionally, the root canal system might be composed of a series of branches.³⁵ Of the many branches that can be found, the present study identified the presence of an intercanal after filling, a branch that connects the main canals and is located at the dentin, thus not affecting the sealer. Such identification was made possible by a combination of the aforementioned factors: cleaning the area with irrigating solution, associated with hermetic sealing allowed by thermoplasticized filling.

It is of paramount importance that tooth restoration, whether extensive or not, be carried out for crown reconstruction after endodontic treatment. The goals of restoration are the integrity of filling and stability of crown reconstruction with a view to recovering tooth function.³⁶ In the present case

report, permanent restorative treatment would be carried out in the week following endodontic treatment; however, the patient did not return to the dental office for restorative treatment and tooth extraction.

References

- Schilder H. Filling root canals in three dimensions. 1967. *J Endod*. 2006;32(4):281-90.
- Slowey RR. Root canal anatomy. Road map to successful endodontics. *Dent Clin North Am*. 1979 Oct;23(4):555-73.
- Miyagaki DC, Lacerda AC, Cecchin D, Ferraz CCR. Mandibular first premolar with three canals and two roots: a case report. *Dental Press Endod*. 2013;3(3):74-7.
- Portela CP, Baratto Filho F, Tomazinho FSF, Correr GM, Moro A, Moresca RC. Estudo da anatomia interna dos pré-molares. Revisão de literatura. *Odontol*. 2011;19(37):63-72.
- Hess W. The anatomy of the root canals of the teeth of the permanent dentition. 1st ed. Londres: John Bale, Sons and Danielsson; 1925.
- Okumura T. Anatomy of the root canals. Transactions of the Seventh International Dental Congress; 1926 Aug 23-27; Philadelphia, PA; 1926. p. 170.
- De Deus QD. A inclusão de dentes diafanizados em plásticos transparentes. Considerações preliminares. *Arq Cent Est Odont UFMG*. 1967;4:197-201.
- Pineda F, Kuttler Y. Mesiodistal and buccolingual roentgenographic investigation of 7,275 root canals. *Oral Surg Oral Med Oral Pathol*. 1972 Jan;33(1):101-10.
- Dotto SR, Pagliarin CML, Carvalho MGP, Travassos RMC, Rosa RA. Tratamento endodôntico de pré-molar inferior com três condutos radiculares: relato de caso clínico. *Rev Endod Pesq Ensino On Line*. 2007;3(6):1-7.
- Vertucci FJ, Gegauff A. Root canal morphology of the maxillary first premolar. *J Am Dent Assoc*. 1979 Aug;99(2):194-8.
- Vertucci FJ. Root canal anatomy of the human permanent teeth. *Oral Surg Oral Med Oral Pathol*. 1984 Nov;58(5):589-99.
- Neves FS, Barbosa JP, Rebello IC. Utilização da tomografia computadorizada de feixe cônico na endodontia. *ClipeOdonto*. 2013;5:58-64.
- Yu X, Guo B, Li KZ, Zhang R, Tian YY, Wang H, et al. Cone-beam computed tomography study of root and canal morphology of mandibular premolars in a western Chinese population. *BMC Med Imaging*. 2012 July 20;12:18.
- Shetty A, Hegde MN, Tahiliani D, Shetty H, Bhat GT, Shetty S. A three-dimensional study of variations in root canal morphology using Cone-Beam Computed Tomography of mandibular premolars in a South Indian population. *J Clin Diagn Res*. 2014 Aug;8(8):ZC22-ZC24.
- Ok E, Altunsoy M, Nur BG, Aglarci OS, Çolak M, Güngör E. A cone-beam computed tomography study of root canal morphology of maxillary and mandibular premolars in a Turkish population. *Acta Odontol Scand*. 2014 Nov;72(8):701-6.
- Bulut DG, Kose E, Ozcan G, Sekerci AE, Canger EM, Sisman Y. Evaluation of root morphology and root canal configuration of premolars in the Turkish individuals using cone beam computed tomography. *Eur J Dent*. 2015 Oct-Dec;9(4):551-7.
- Theruvil R, Ganesh C, George AC. Endodontic management of a maxillary first and second premolar with three canals. *J Conserv Dent*. 2014;17(1):88-91.
- Nallapati S. Three-canal maxillary premolar teeth: a common clinical reality. *Endod Pract*. 2003;6:22-8.
- Ashraf H, Paymanpour P, Bidabadi MM, Hajrezai R. Healing of an extensive periradicular lesion subsequent to a proper endodontic treatment of a mandibular first premolar with complex anatomy. *Case Rep Dent*. 2013;2013:972093.
- Leonardo MR. Endodontia: tratamento de canais radiculares: princípios técnicos e biológicos. 1a ed. São Paulo: Artes Médicas; 2005.
- Pinheiro Júnior EC, Leite APP, Silva RG, Pecora DJ. Relação entre sulcos radiculares e número de canais em pré-molares inferiores. Estudo "in vitro". *Rev Assoc Bras Odontol ABO Nacional*. 1994;2(4):265-9.
- Zhang D, Chen J, Lan G, Li M, An J, Wen X, et al. The root canal morphology in mandibular first premolars: a comparative evaluation of cone-beam computed tomography and micro-computed tomography. *Clin Oral Investig*. 2016 May 13. [Epub ahead of print].
- Llena, C, Fernandez J, Ortolani OS, Forner L. Cone-beam computed tomography analysis of root and canal morphology of mandibular premolars in a Spanish population. *Imaging Sci Dent*. 2014 Sept;44(3):221-7.
- Kierklo A, Tabor Z, Pawińska M, Jaworska M. A microcomputed tomography-based comparison of root canal filling quality following different instrumentation and obturation techniques. *Med Princ Pract*. 2015;24(1):84-91.
- Cohen S, Hargreaves KM. Caminhos da polpa. 10ª ed. São Paulo: Elsevier; 2011.
- Ricucci D. Apical limit of root canal instrumentation and obturation, part 1. Literature review. *Int Endod J*. 1998 Nov;31(6):384-93.
- Holland R, Mazuqueli L, Souza V, Murata SS, Dezan Júnior E, Suzuki P. Influence of the type of vehicle and limit of obturation on apical and periapical tissue response in dogs' teeth after root canal filling with mineral trioxide aggregate. *J Endod*. 2007 June;33(6):693-7.
- White RR, Goldman M, Lin PS. The influence of the smeared layer upon dentinal tubule penetration by plastic filling materials. *J Endod*. 1984 Dec;10(12):558-62.
- Shenoy A, Amahduddin, Bolla N, Raj S, Mandava P, Nayak S. Effect of final irrigating solution on smear layer removal and penetrability of the root canal sealer. *J Conserv Dent*. 2014 Jan-Feb;17(1):40-4.
- Singh N, Chandra A, Tikku AP, Verma P. A comparative evaluation of different irrigation activation systems on smear layer removal from root canal: An in-vitro scanning electron microscope study. *J Conserv Dent*. 2014 Mar-Apr;17(2):159-63.
- Ahri B, Parekh V, Katyayan MK, Katyayan PA. Smear layer removal efficacy of different irrigating solutions: a comparative scanning electron microscope evaluation. *Indian J Dent Res*. 2014 Sept-Oct;25(5):617-22.
- Migliari G, Sofan AA, Sofan EA, Cosma S, Eramo S, Gallottini L. Root canal obturation: experimental study on the thermafil system related to different irrigation protocols. *Ann Stomatol (Roma)*. 2014 July-Sept;5(3):91-7.
- Camões ICG, Victor FL, Gomes CC, Freitas LF, Pinto SS. Estudo comparativo entre duas técnicas obturadoras: condensação lateral X híbrida de Tagger. *Pesq Bras Odontopediatria Clin Integ*. 2007;7(3):217-22.
- Tavares WLF, Lopes RCP, Borges DCPC, Henriques LCF, Ribeiro Sobrinho AP. Opção pela técnica híbrida de Tagger para obturação de canais radiculares em clínica de pós-graduação em endodontia. *Arq Odontol*. 2012 Jan-Mar;48(1):26-31.
- De Deus QD. Endodontia. 1ª ed. Rio de Janeiro: Medsi; 1992.
- Guttmann JL, Lovdahl PE. Soluções em Endodontia: prevenção, identificação e procedimentos. 5ª ed. Rio de Janeiro: Elsevier; 2012.

Conclusion

Knowing and mastering root canal anatomical traits are key to achieve success in endodontic treatment.