

# Effectiveness evaluation of three obturation techniques in the filling of a simulated internal root resorption area

Cheila **FOCCHI**<sup>1</sup>

Tiago André Fontoura de **MELO**<sup>2</sup>

DOI: <http://dx.doi.org/10.14436/2358-2545.7.1.071-077.oar>

## ABSTRACT

**Objective:** This study aimed to analyze the effectiveness of three filling techniques for experimental cavities with internal root resorption. **Methods:** A total of 30 artificial maxillary central incisors with a standardized simulated cavity with internal resorption in the middle third of the root canal were used. After preparation, the teeth were randomly divided into three experimental groups according to the filling technique used: McSpadden™ compactor (group 1), ultrasound (group 2), and Term Pack WL™ (group 3). Endodontic filling of the internal resorption cavity was verified via radiography in two views: mesiodistal and buccolingual. For analysis

of the filling area, Image Tool™ software was used. Data were statistically analyzed by ANOVA, followed by Tukey's test, with 5% significance level. **Results:** Analysis of the three filling techniques revealed the use of McSpadden™ compactor and Term Pack WL™ provided better filling of the resorption cavity than that shown by the use of the ultrasonic spreader. **Conclusion:** Only McSpadden™ compactor and Term Pack WL™ completely filled the internal root resorption cavity with root canal filling material.

**Keywords:** Endodontics. Tooth resorption. Root canal filling. Digital dental radiography. Dental instruments.

**How to cite:** Focchi C, Melo TAF. Effectiveness evaluation of three obturation techniques in the filling of a simulated internal root resorption area. *Dental Press Endod.* 2017 Jan-Apr;7(1):71-7.  
DOI: <http://dx.doi.org/10.14436/2358-2545.7.1.071-077.oar>

» The authors report no commercial, proprietary or financial interest in the products or companies described in this article.

Submitted: September 30, 2016. Revised and accepted: January 17, 2017.

<sup>1</sup>Private practice (Bento Gonçalves/RS, Brasil).

<sup>2</sup>Universidade Federal do Rio Grande do Sul, Faculdade de Odontologia, Departamento de Odontologia Conservadora (Porto Alegre/RS, Brasil).

Contact address: Tiago André Fontoura de Melo  
Rua Nicola Mathias Falci, 151 / casa 16  
Bairro Jardim do Salso – Porto Alegre/RS  
CEP: 91.410-330 – E-mail: tafmelo@gmail.com

## Introduction

Internal root resorption is a pathological lesion usually associated with histological pulp inflammation.<sup>1</sup> According to Consolaro et al,<sup>2</sup> the stimulus inducing the internal resorption process is characterized by being of long-term and low intensity. It should not be enough to promote pulp necrosis, but quite enough to trigger a chronic inflammatory condition.

Spontaneous repair of an internal resorptive process is extremely rare.<sup>3</sup> When internal resorption is diagnosed, endodontic therapy carried out by means of pulpectomy must be performed to remove the inflamed tissue and stop blood flow which nurtures clastic cells and the dentin-destructive process.<sup>4-7</sup>

Most cases of internal root resorption are diagnosed via routine radiographs. This injury radiographically appears as an oval radiolucent area with uniform and symmetrical contours along the dentinal wall of the root canal.<sup>8,9</sup> Thus, some difficulties persist in the treatment of teeth with internal resorption, including access to the resorbed area owing to the complex cleaning process, sanitation, removal of granulation tissue,<sup>10,11</sup> and filling the root canal with filling material.<sup>12,13</sup>

To obtain adequate filling and sealing of the internal resorption area during the filling process, the filling material must have a certain level of fluidity in order to facilitate penetration and flow throughout the length of the cavity.<sup>14</sup> Gutta-percha, commonly used in the filling process, requires preheating to provide the aforementioned flow.

Studies have shown there are differences among filling methods, particularly regarding their capacity to fill the resorption cavity.<sup>15-18</sup> In a study conducted by Goldberg et al,<sup>19</sup> it was observed that Obtura II™ system provided better filling of experimental cavities with internal resorption than that provided by other techniques, such as lateral condensation, Tagger's hybrid technique, and use of Thermafil™.

Thus, this study aimed to analyze the effectiveness of three different systems used for plasticization of gutta-percha used to fill experimental cavities with internal root resorption: McSpadden™ compactor, ultrasound, and shutter-heated Term Pack WL™.

## Material and Methods

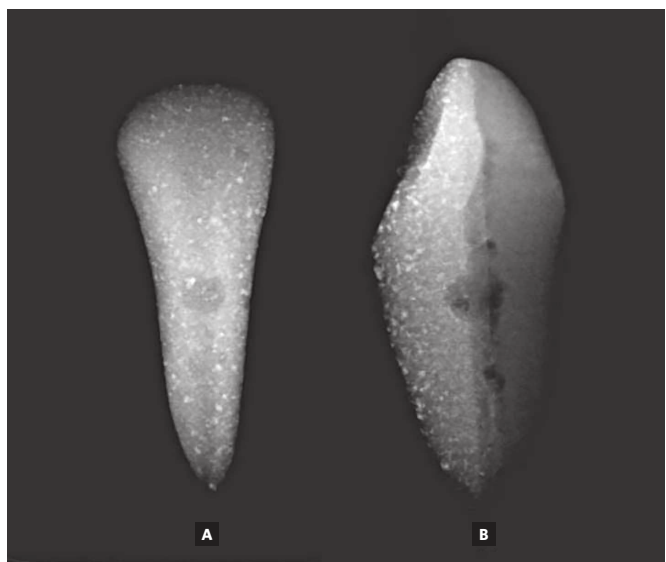
### Selection and preparation of samples

A total of 30 artificial maxillary central incisors on the left side were used (Fábrica de Sorrisos, Arujá, São Paulo, Brazil) with the presence of a cavity in the middle third of the root canal simulating internal root resorption (Fig 1).

Access to the pulp chamber of teeth was attained with the aid of a #1012 cylindrical diamond bur tip (KG Sorensen Indústria e Comércio Ltda., Barueri, São Paulo, Brazil), coupled with a high-speed hand-piece under refrigeration.

Upon completion of crown opening, the root canal was located with a Rhein #3 probe (Golgran Indústria e Comércio de Instrumental Odontológico Ltda., São Paulo, São Paulo, Brazil). Subsequently, the working length (WL) was determined with the use of a K-file #15 (Dentsply/Maillefer, Ballaigues, Switzerland), 1mm short the foramen output. The WL of all teeth was standardized at 20mm.

Prior to conducting mechanical-chemical preparation, cervical ripening was performed with La Axxess™ bur (SybronEndo, Glendora, USA) 0.06 taper key #20 at a standardized distance of penetration in the root canal equal to 8mm from the incisal edge.



**Figure 1.** Radiographic buccolingual (A) and mesiodistal (B) images of the artificial central incisor with a cavity in the middle third of the root canal simulating internal root resorption.

For root canal preparation, endodontic K-files (Dentsply/Maillefer, Ballaigues, Switzerland) were used, first and second series, following the stepwise technique with a programmed gradual decline. As memory instrument, # 45 was standardized, with scaling performed up to instrument #60. The limit for the number of uses of each endodontic instrument was standardized in five teeth.

After instrument exchange, root canals were irrigated with 1ml of distilled water (Iodontec Indústria e Comércio de Produtos Odontológicos Ltda., Porto Alegre, Rio Grande do Sul, Brazil). With a view to avoiding overflow of irrigating solution from the foraminal opening, light-curing was performed with an increment of Fill Magic (Vigodent Coltène SA Industry and Commerce, Rio de Janeiro, Brazil) composite resin in the apical vertex.

After preparation of teeth, they were randomly divided into three groups according to the filling technique used: McSpadden™ compactor (group 1), ultrasound (group 2), and Term Pack WL™ (group 3) (Fig 2). Each group comprised ten samples.

## Filling of samples

After drying root canals with absorbent paper cones (Tanari™, Manaus, Amazonas, Brazil) #45 at WL, the main gutta-percha cone (Tanari™, Manaus, Amazonas, Brazil) suitable for each root canal was selected.

During the filling process, endodontic sealer Endofill™ (Dentsply/Maillefer, Ballaigues, Switzerland), which was handled according to the manufacturer's instructions, was combined with accessory gutta-percha B7 points (Tanari™, Manaus, Amazonas, Brazil).

In all teeth, initial filling protocol was the same. The main cone surrounded by sealer was taken up to WL. Subsequently, five accessory points were coated with sealer and used at spaces created with bidigital B spreader (Dentsply/Maillefer, Ballaigues, Switzerland).

Root canals in which McSpadden™ compactor (group 1) was used, the following protocol was applied: after placement of the fifth accessory point, gutta-percha cones were plasticized with the aid of



**Figure 2.** Devices used in the three experimental groups: McSpadden™ compactor (A), bidigital B spreader intermediate component coupled to ENDO L ultrasonic insert (B), and Term Pack WL™ (C).

McSpadden™ #60 (Dentsply/Maillefer, Ballaigues, Switzerland) calibrated 4mm short the WL, with a view to filling both cervical and middle thirds of the root canal. The compactor, driven in clockwise direction in the low-rotating handpiece, was introduced and withdrawn in motion from the root canal. After gutta-percha plasticization and McSpadden™-removal, vertical gutta-percha condensation was achieved with the aid of Paiva condenser #2 (S.S. White, Rio de Janeiro, Brazil).

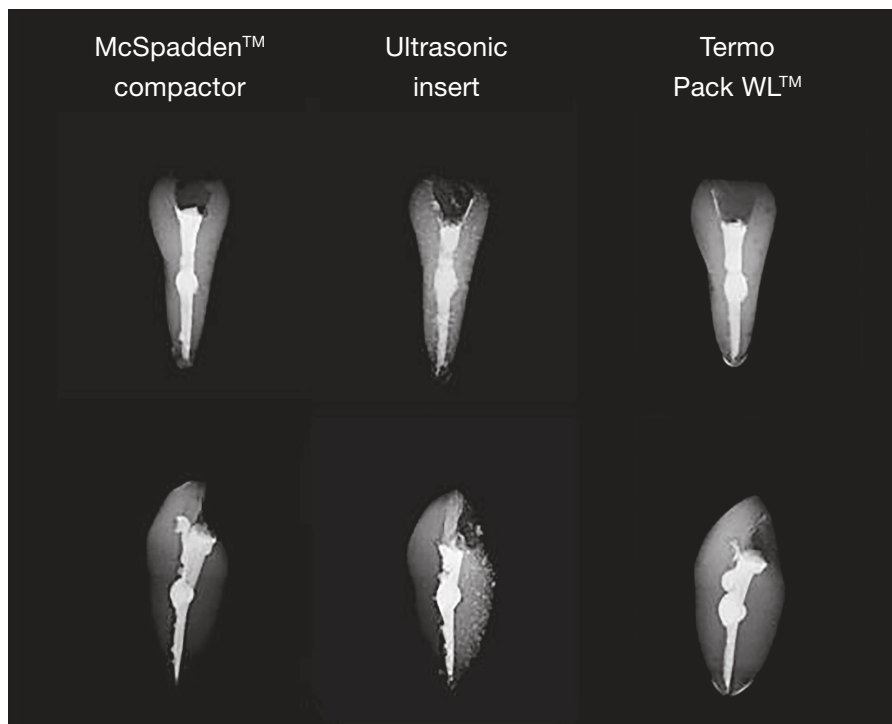
As for root canals in which ultrasound was used (group 2), the following protocol was applied: after placement of the fifth accessory point, gutta-percha cones were plasticized with the aid of ENDO L ultrasonic insert (Dabi Atlante, Ribeirão Preto, São Paulo, Brazil), to which a bidigital B spreader intermediate component was coupled. The insert inside the root canal was driven with 50% power, unrefrigerated, and set in Profi Class device (Dabi Atlante, Ribeirão Preto, São Paulo, Brazil). Standard activation time was 20 seconds. The spreader was calibrated 4mm short the WL, with a view to filling both cervical and middle thirds of the root canal. After gutta-percha plasticization, vertical gutta-percha condensation was achieved with the aid of Paiva condenser #2.

Teeth in which Term Pack WL™ (group 3) was used, the following protocol was applied: after placement of the fifth accessory point, gutta-percha cones were sectioned along the apical third of the root canal with the aid of a metal tip cutting device. Subsequently, cold condensation of gutta-percha was performed with the same tip. Afterwards, the internal resorption area and root canal cervical third were filled with flowable gutta-percha produced by Term Pack WL™ (Easy Equipamentos Odontológicos, Belo Horizonte, Minas Gerais, Brazil). It was then taken into the root canal with McSpadden™ compactor #60. After root canal filling with gutta-percha, vertical condensation was achieved with the aid of Paiva condenser #2.

All root canal procedures were performed by the same clinician. Teeth were temporarily sealed with Cavit™ (ESPE Dental Medzin, Germany).

### Endodontic filling analysis

Endodontic filling of the internal resorption cavity was verified via radiography in two views: mesiodistal and buccolingual, thus allowing examination of buccal and proximal surfaces of each sample (Fig. 3).



**Figure 3.** Endodontic filling in both radiographic views in all three techniques tested.

Radiographs were obtained by securing each tooth to the surface of the Cygnus Ray MPS digital X-ray sensor (Progeny Dental). Radiographic examination was achieved with an imaging equipment (TIMEX 70C, Gnatus Equipamentos Médico-Odontológicos Ltda.), set at 70kV, 08 mA, and exposure time of 0.20 seconds, and positioned so that the central beam was perpendicularly incised to the sensor with 40-cm focal length. This step was standardized by means of a radiographic platform.

Digital radiographs were sent to a Pentium 4 computer (Intel Inside™) in which Image Tool™ software (UTHSCA, San Antonio, TX, USA) was used to measure the filled area.

In order to calculate the percentage of the filled area, the total area of the internal resorption cavity was estimated, corresponding to 100%, whereas the filled corresponded to “X.”

### Statistical analysis

Data were statistically analyzed by ANOVA followed by Tukey’s test. The significance level was set at 5%. Statistical analysis was performed with the aid of SPSS version 22.0 (SPSS Inc, Chicago, IL, USA).

### Results

Table 1 shows mean values relative to resorption cavities filling in the three experimental groups. McSpadden™ compactor and Term Pack WL™ provided better filling of the internal resorption cavity in comparison to that shown by the ultrasonic spreader used for plasticization of gutta-percha. No statistically significant differences were found between McSpadden™ compactor and Term Pack WL™.

### Discussion

Studies such as those conducted by Argawal et al<sup>20</sup> and Gençoğlu et al<sup>12</sup> found that filling with root canals presenting with anatomical irregularities, irrespective of their origin, is best performed when systems or devices aimed at gutta-percha plasticization are employed, particularly when compared to the conventional technique of lateral cold condensation. Thus, the filling techniques analyzed in the present study followed the aforementioned principle, so as to promote better material flow within internal resorption cavities.<sup>21</sup>

The purpose of choosing artificial teeth for the experiment was to standardize samples by keeping all areas of root resorption in the same position and maintaining a similar cavity diameter. Maxillary central incisors were chosen due to having the highest prevalence of internal resorption.<sup>22</sup> As for the location of pathology most cases are found in the middle third of the root canal.<sup>23</sup>

Analysis of filling of simulated internal root resorption areas was carried out with the aid of the “area” tool provided by Image Tool™ software, as well as on the basis of a study conducted by Gençoğlu et al.<sup>12</sup>

Analysis of results reveals the use of McSpadden™ compactor and Term Pack WL™ provided better filling of the resorption cavity with the filling material, particularly when compared to the ultrasonic spreader. It is believed that filling achieved with filling material in teeth from the Term Pack WL™ group was directly influenced by propulsion produced with activation achieved by McSpadden™ compactor. The use of McSpadden™ compactor for gutta-percha plasticization promoted a better

**Table 1.** Comparison of mean filling capacity in experimental internal root resorption cavities among the three proposed techniques.

Experimental group	Filling resorption area (%)	
	Buccolingual view	Mesiodistal view
McSpadden™ compactor	100 <sup>A</sup>	100 <sup>A</sup>
Ultrasound	88,9 <sup>B</sup>	87,4 <sup>B</sup>
Term Pack WL™	100 <sup>A</sup>	100 <sup>A</sup>
<b>p-value</b>	<b>0,008</b>	<b>0,007</b>

Means followed by different capital letters in column differ significantly by ANOVA, followed by the Multiple Comparison Tukey’s Test, at a significance level of 5%.

flow of filling material, as seen in studies conducted by Tagger et al<sup>24</sup> and Melo et al.<sup>13</sup> Goldberg et al<sup>19</sup> found that injectable gutta-percha systems, such as the Obtura II™, are more effective in filling of irregularities than tips aimed at thermoplasticization. Gençoglu et al<sup>12</sup> also achieved excellent results with the Obtura II™ system.

Conversely, Ulusoy et al<sup>25</sup> found that injectable gutta-percha placement (Obtura II™ System) into the internal resorption cavity causes temperature to rise in the external root surface above acceptable critical limits. This can cause damage to supporting tissues.

Although ultrasonic insert activation generates thermal energy capable of plasticizing gutta-percha into the root canal,<sup>26</sup> results achieved in the study carried out with it were not satisfactory, thus corroborating Moreno,<sup>27</sup> Argawal et al,<sup>20</sup> and Melo et al.<sup>13</sup> According to Baumgardner and Krell<sup>28</sup> as well as Bailey et al,<sup>29</sup> whose studies were conducted with an ultrasonic system during filling, greater compaction of filling material is achieved, thus resulting in less voids and lower leakage rates.

In a study conducted by Argawal et al,<sup>20</sup> the authors also reported having difficulty in assessing areas of resorption with the aid of two-dimensional radiographic images of a three-dimensional object. Hence, the present study used both buccolingual as well as mesiodistal radiographic views, so as to be able to better assess the filled area. Both radiographic views were similar in terms of quality of filling material in all three techniques tested, differing from results achieved by Melo et al<sup>13</sup> whose study was carried out with ultrasound. The results were similar with the use of McSpadden™ compactor. Goldberg et al<sup>19</sup> found a lower degree of filling of the internal root resorption cavity in mesiodistal view compared with that in buccolingual view.

## Conclusions

According to the results achieved by the present study, the following conclusions can be drawn:

The use of McSpadden™ compactor and Term Pack WL™ provided better filling of the resorption cavity compared with that shown by the use of the ultrasonic spreader.

## References

- Al-Momani Z, Nixon PJ. Internal and external root resorption: aetiology, diagnosis and treatment options. *Dent Update*. 2013 Mar;40(2):102-4, 107-8, 111-2.
- Consolaro A, Consolaro RB, Prado RF. Reabsorção interna: uma pulpopatia inflamatória. In: Consolaro A. *Reabsorções dentárias nas especialidades clínicas*. 3ª ed. Maringá: Dental Press; 2012. cap. 11, p. 315-43.
- Callışkan MK, Pişkin B. Internal resorption occurring after accidental extrusion of iodoform paste into the mandibular canal. *Endod Dent Traumatol*. 1993 Apr;9(2):81-4.
- Bakland LK. Root resorption. *Dent Clin North Am*. 1992 Apr;36(2):491-507.
- Ne RF, Witherspoon DE, Gutmann JL. Tooth resorption. *Quintessence Int*. 1999 Jan;30(1):9-25.
- Araujo LCG, Lins CV, Lima GA, Lima GA, Travassos RMC, Lins CCSA. Study of prevalence of internal resorption in periapical radiography of anterior permanent tooth. *Int J Morphol*. 2009;27(1):227-30.
- Patel S, Ricucci D, Durak C, Tay F. Internal root resorption: a review. *J Endod*. 2010 July;36(7):1107-21.
- Gartner AH, Mack T, Somerlott RG, Walsh LC. Differential diagnosis of internal and external root resorption. *J Endod*. 1976 Nov;2(11):329-34.
- Wedenberg C, Lindskog S. Experimental internal resorption in monkey teeth. *Endod Dent Traumatol*. 1985 Dec;1(6):221-7.
- Topçuoğlu HS, Akti A, Düzgün S, Ceyhanlı KT, Topçuoğlu G. Effectiveness of different irrigation procedures for removal of dentin debris from a simulated internal resorption cavity. *Int J Artif Organs*. 2015 Mar;38(3):165-9.
- Topçuoğlu HS, Düzgün S, Ceyhanlı KT, Akti A, Pala K, Kesim B. Efficacy of different irrigation techniques in the removal of calcium hydroxide from a simulated internal root resorption cavity. *Int Endod J*. 2015 Apr;48(4):309-16.
- Gencoglu N, Yildirim T, Garip Y, Karagenc B, Yilmaz H. Effectiveness of different gutta-percha techniques when filling experimental internal resorptive cavities. *Int Endod J*. 2008 Oct;41(10):836-42.
- Melo TAF, Kunert GG, Silva MB, Cabeda MF. Eficácia de duas técnicas de obturação em cavidades experimentais de reabsorção radicular interna. *Rev Odontol UNESP*. 2014;43(6):367-71.
- Özer YS. Diagnosis and treatment modalities of internal en external cervical root resorptions: review of the Literature whit case reports. *Int Dent Res*. 2011;1:32-7.
- Andreasen FM, Sewerin I, Mandel U, Andreasen JO. Radiographic assessment of simulated root resorption cavities. *Endod Dent Traumatol*. 1987 Feb;3(1):21-7.
- Collins J, Walker MP, Kulild J, Lee C. A comparison of three gutta-percha obturation techniques to replicate canal irregularities. *J Endod*. 2006 Aug;32(8):762-5.
- Kulild J, Lee C, Dryden J, Collins J, Feil P. A comparison of 5 gutta-percha obturation techniques to replicate canal defects. *Oral Surg Oral Med Oral Pathol Oral Radiol Endod*. 2007 Jan;103(1):e28-32.
- Keles A, Ahmetoglu F, Uzun I. Quality of different gutta-percha techniques when filling experimental internal resorptive cavities: a micro-computed tomography study. *Aust Endod J*. 2014;40:131-5.
- Goldberg F, Massone EJ, Esmoris M, Alfie D. Comparison of different techniques for obturating experimental internal resorptive cavities. *Endod Dent Traumatol*. 2000 June;16(3):116-21.
- Agarwal M, Rajkumar K, Lakshminarayanan L. Obturation of internal resorption cavities with 4 different techniques: an in-vitro comparative study. *Endodontol*. 2002;14:3-8.
- Wilson PR, Barnes IE. Treatment of internal root resorption with thermoplasticized gutta-percha. A case report. *Int Endod J*. 1987 Mar;20(2):94-7.
- Coll Juanes M, Giokouria Cuadra I, Aguirre Urizar JM. Internal tooth resorption. *Rev Actual Odontoestomatol Esp*. 1990;50:39-43.
- Callışkan MK, Türkün M. Prognosis of permanent teeth with internal resorption: a clinical review. *Endod Dent Traumatol*. 1997 Apr;13(2):75-81.
- Tagger M, Tamse A, Katz A, Korzen BH. Evaluation of the apical seal produced by a hybrid root canal filling method, combining lateral condensation and thermatic compaction. *J Endod*. 1984 July;10(7):299-303.
- Ulusoy ÖI, Yılmazoğlu MZ, Görgül G. Effect of several thermoplastic canal filling techniques on surface temperature rise on roots with simulated internal resorption cavities: an infrared thermographic analysis. *Int Endod J*. 2015 Feb;48(2):171-6.
- Park E. Ultrasonics in endodontics. *Endod Top*. 2013;29(1):125-59.
- Moreno W. Thermomechanically softened gutta-percha root canal filling. *J Endod*. 1977 May;3(5):186-8.
- Baumgardner KR, Krell KV. Ultrasonic condensation of gutta-percha: an in vitro dye penetration and scanning electron microscopic study. *J Endod*. 1990 June;16(6):253-9.
- Bailey GC, Ng YL, Cunnington SA, Barber P, Gulabivala K, Setchell DJ. Root canal obturation by ultrasonic condensation of gutta-percha. Part II: an in vitro investigation of the quality of obturation. *Int Endod J*. 2004 Oct;37(10):694-8.